



# Neck and Upper Extremity Pain Syndromes

---

David M Glick, DC, DAIPM, CPE, FASPE

# Disclosure

---

- None

# Course Objectives

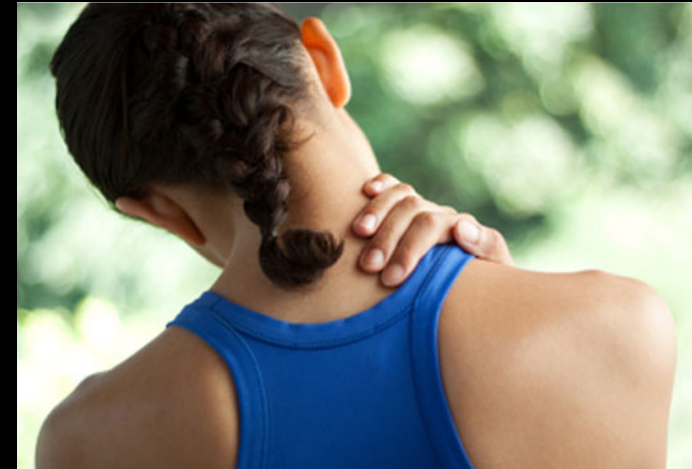---

- Identify primary and secondary pain generators that contribute to neck and upper extremity pain.
- Describe how regional examinations may be deficient in providing adequate differential diagnosis of neck and upper extremity pain syndromes
- Demonstrate how overlapping clinical pathologies can exist and complicate clinical presentations

# Misconceptions of Neck Pain

---

- Neck pain is Symptom not a pathology.
- All neck pain is not caused by disc herniations or “pinched nerves.”
- There is no single treatment to address neck pain.
- Chronic neck pain often occurs from failure to adequately diagnose and treat.



# What about the Clinician?

---

- Highly skilled, well rounded, just not familiar with the particular problem.
- Not every clinician can treat every problem
- Diagnostic triage can hold the key to successful clinical outcomes.



# Most Important Tools for Differential Diagnosis...

---

- History
- Clinical Examination
- Experience of Clinician



# Adverse Factors Affecting Patient Centered Diagnosis

---

- Limitations of Time

- *Volume of patients may limit face-to-face time with clinician.*
  - *Reimbursements tend to devalue clinical component.*

- Reliance Upon Technology

- *MRI shows disc herniations so that must be the cause of the patient's neck pain.*

- Clinical Experience

- *Has the clinician evaluated patients with similar symptoms before*

# MRI of cervical intervertebral discs in asymptomatic subjects

---

- 497 **asymptomatic** subjects evaluated by cervical MRI
- Frequency of all degenerative findings increased linearly with age
- Disc degeneration was the most common observation
  - 17% males / 12% females in their twenties
  - **86% male / 89% females over 60 years of age**
- Significant differences in frequency between genders for posterior disc protrusion and foraminal stenosis
- 7.6% of subjects over 50 were identified as having cord compression



# Neck & Upper Extremity Pain Causes

---

- Neuropathic

- Myelopathy
- Radiculopathy
- Plexopathy
- Peripheral entrapments
- Peripheral neuropathies
- Neuromuscular disorders

- Arthropathy

- Neck, shoulder, elbow, wrist, digits

- Tendons

- tendinopathy (tendinosis/sprains)
- Tendonitis/enthesitis

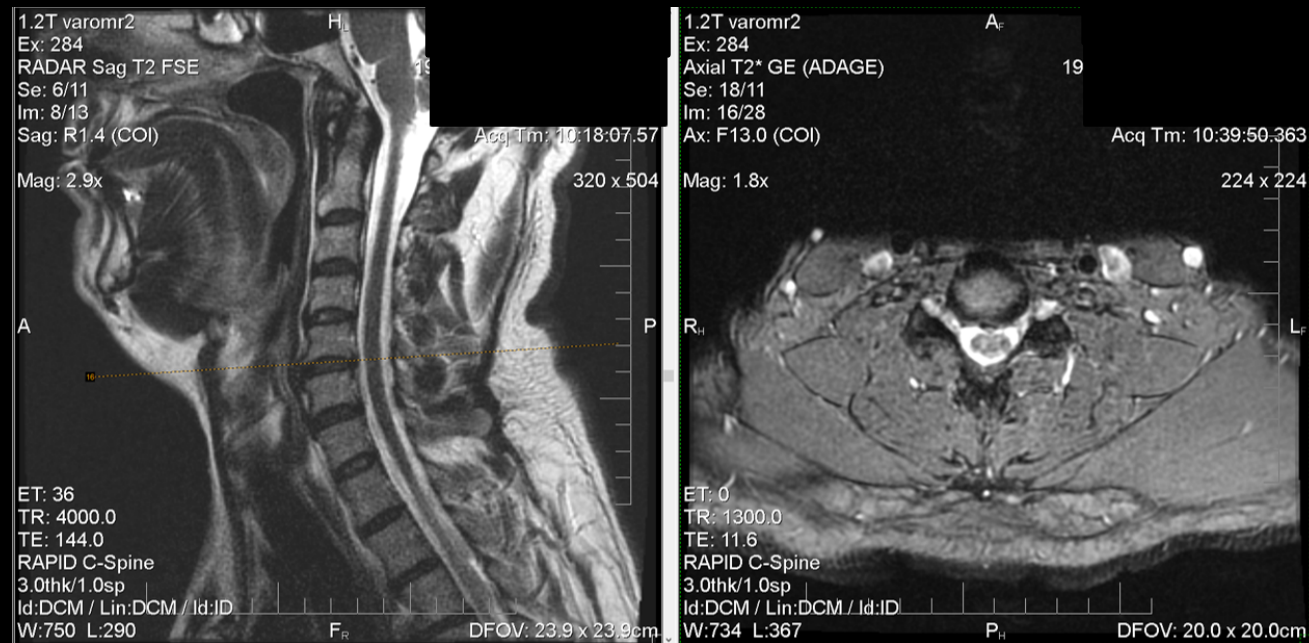- Muscular

- Myopathy
- Strains

- Vascular

- Autonomic

# Typical Patient Scenario Chronic Neck Pain



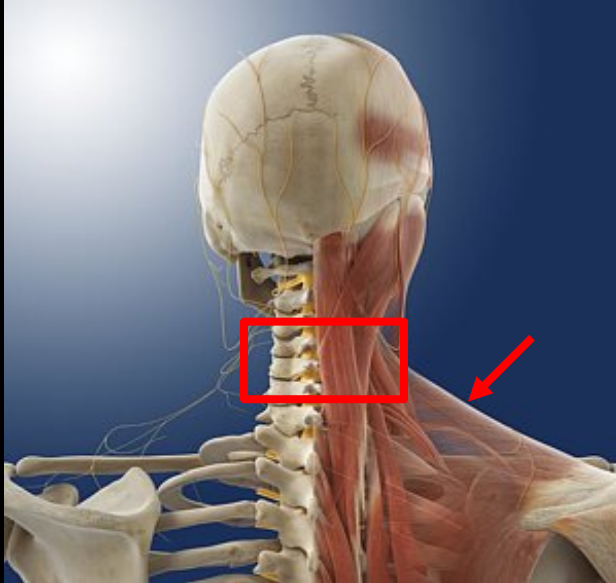**Pt Complaints:** Neck pain (right sided), suboccipital headaches, hx of tingling into the right 3<sup>rd</sup> - 5<sup>th</sup> digits.

**MRI:** Minimal DJD C3 through C6, without evidence of canal or foraminal stenosis.

**Prior Treatments:** PT (exercise, heat and massage), trigger point injections, ESIs, facet injections (medial branch blocks, RF ablations, all without long term benefit.

# Typical Patient Scenario

---



Focus of prior treatments

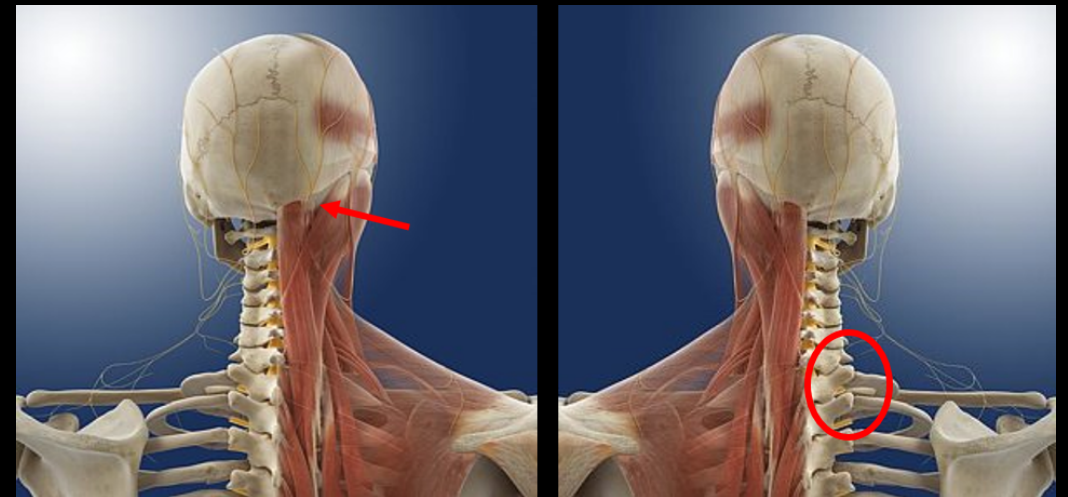
**Prior Treatments:** PT (exercise, heat and massage), trigger point injections, ESIs, facet injections (medial branch blocks, RF ablations, all without long term benefit.

# Typical Patient Scenario

## Clinical examination:

- Tenderness approx. nuchal line (trapezius, semispinalis capitis and splenius capitis muscle origins)\*\*
- Hypertonicity (mild spasm) of trapezius (with shoulder elevation)
- Pain to palpation and local multifidus muscle tenderness over C3/C4 facet joint on the right
- Pain over the right 2<sup>nd</sup> costovertebral joint, and when palpating along right 2<sup>nd</sup> rib\*\*
- Normal DTRs, motor and sensory examination, cervical ROM, Phalen's, Adson's, Wright's, Tinel's, cervical compression, Jacksonian compression and cervical distraction

Areas identified as most severe by the patient



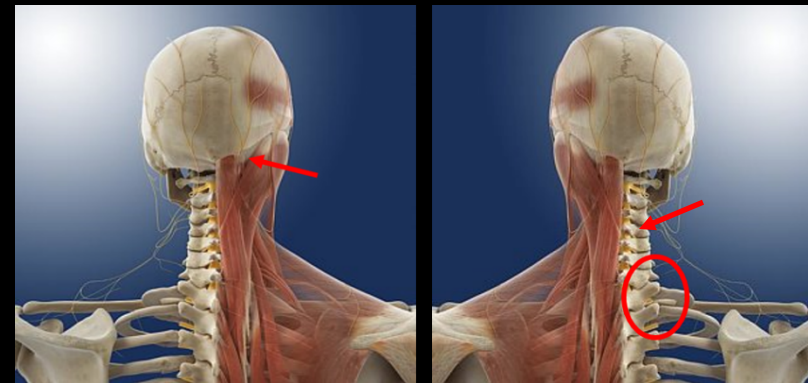
# Revisited Diagnosis and Treatment

## Revised working clinical impression:

- Right-sided suboccipital headaches likely more musculoskeletal in nature secondary to tendonitis-enthesitis of splenius cervicis, splenius capitis, and trapezius muscles. Small possibility of involvement at the greater occipital nerve though not likely.
- Right second rib arthropathy, possibly contributing to mild radiculitis C8/T1
- Right C3/C4 facet irritation, possibly contributing to the trapezius tendonitis/enthesitis

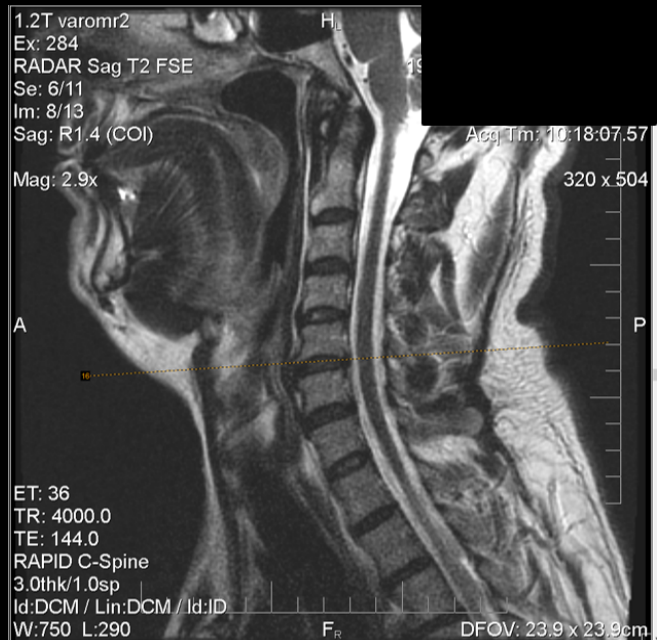## Revised treatment:

- Topical diclofenac suboccipital (*off label use*)
- Manipulation to address the rib arthropathy
- Intra-articular facet injection right C3/C4
- Discontinue medications
- Biopsychosocial coping skills and education



# Clinical Pearl

---

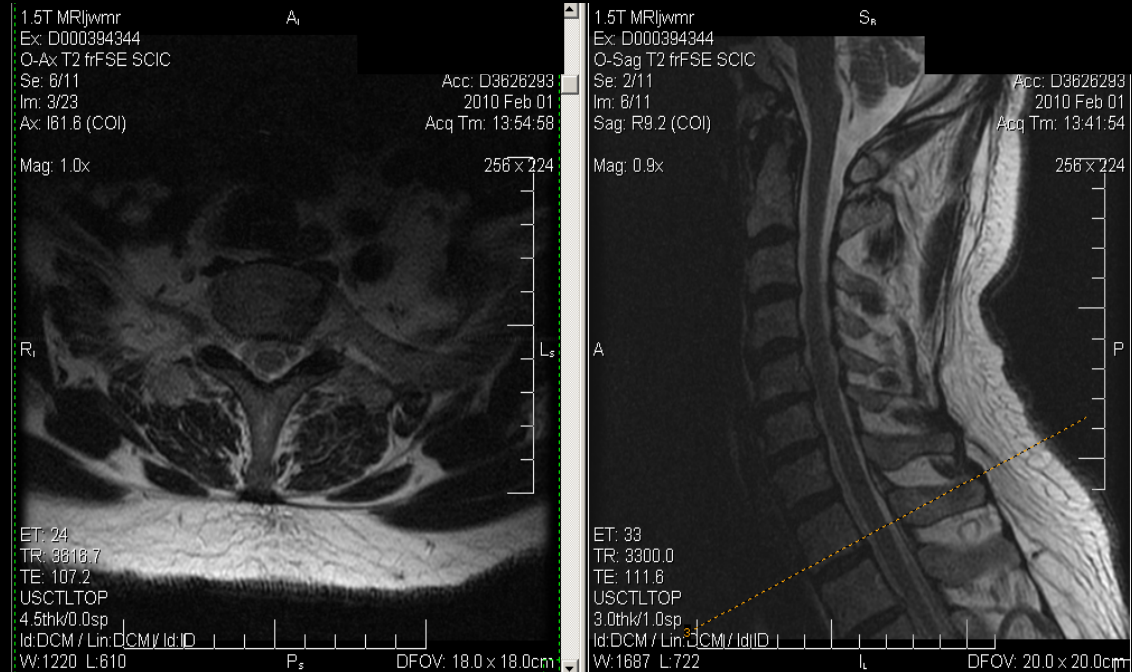
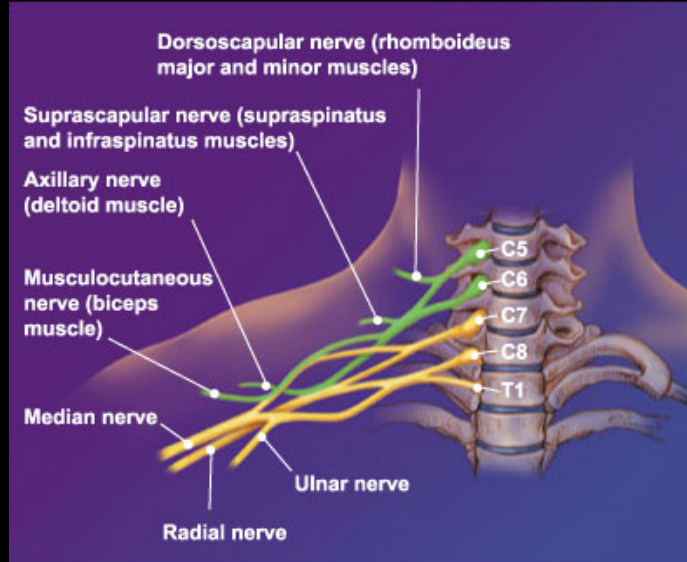


- While providing valuable structural information, they do not necessarily reflect whether a pathology is clinically relevant.
- MRI may demonstrate disc compression of a nerve, but current technology **does not** describe inflammation of a nerve (radiculitis).



# Clinical Pearl

Always request axial images to include C8 & T1 roots on order for Cervical MRI



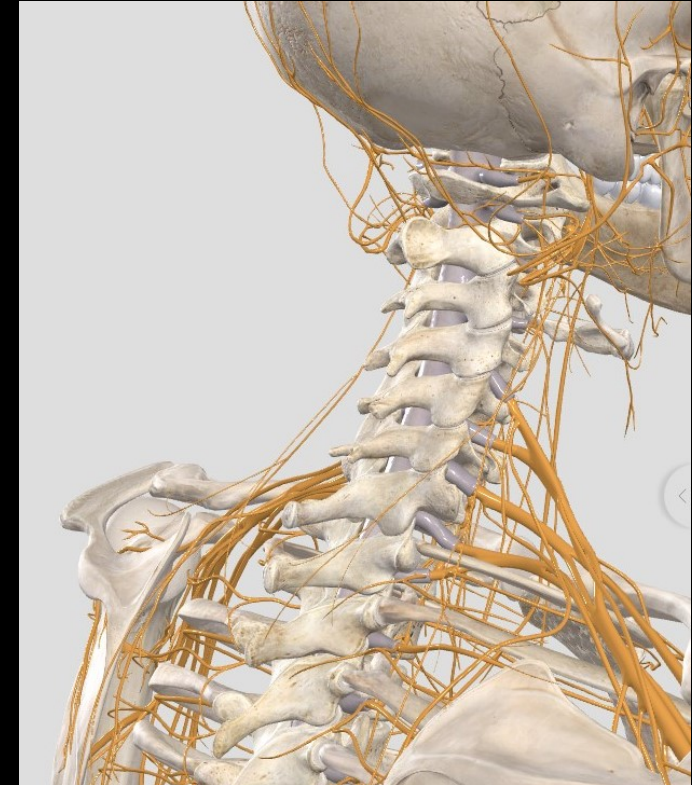
- Brachial Plexus is C5-T1 spinal nerve roots
- All intrinsic muscles of the hand are innervated by C8/T1, as are most muscles for grip
- If upper extremity symptoms extend to hand or include decrease grip strength, then there is a high likelihood C8 or T1 is involved
- Most Cervical MRIs do not image the T1 root, and many do not include C8

# General Anatomy & Pathophysiology – Facet (aka zygapophysial) joints

---

## Inflammation of a facet joint:

- Actual joint pain
- Local muscle spasms (multifidus and other)
  - Limit range of motion or antalgic posturing
- Inflammatory cytokines and other inflammatory mediators can leak out and inflame other local structures, including nerve roots leading to radiculitis
- Inflamed nerve can present sensory complaints along the peripheral distribution - **Radiculitis**
- Muscles innervated by that nerve can become hypertonic (also contribute to referred pain)

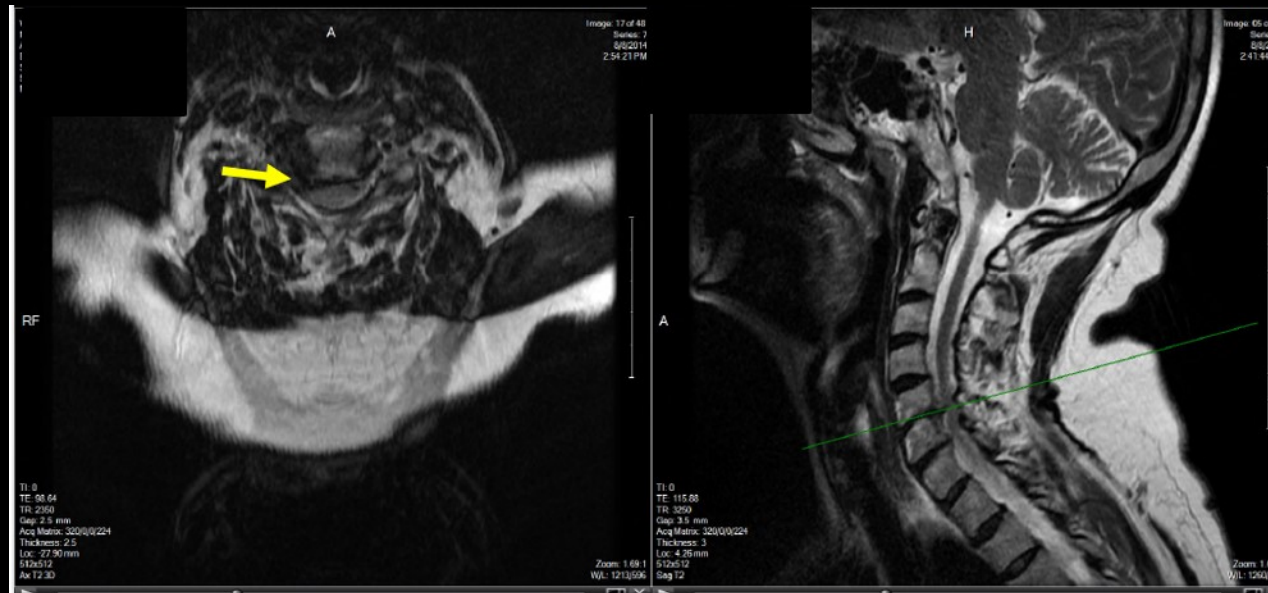




# Disc Herniation with Nerve Root Compression (Expected)

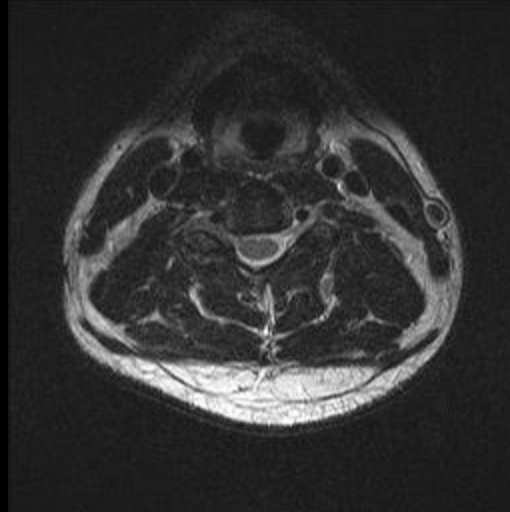
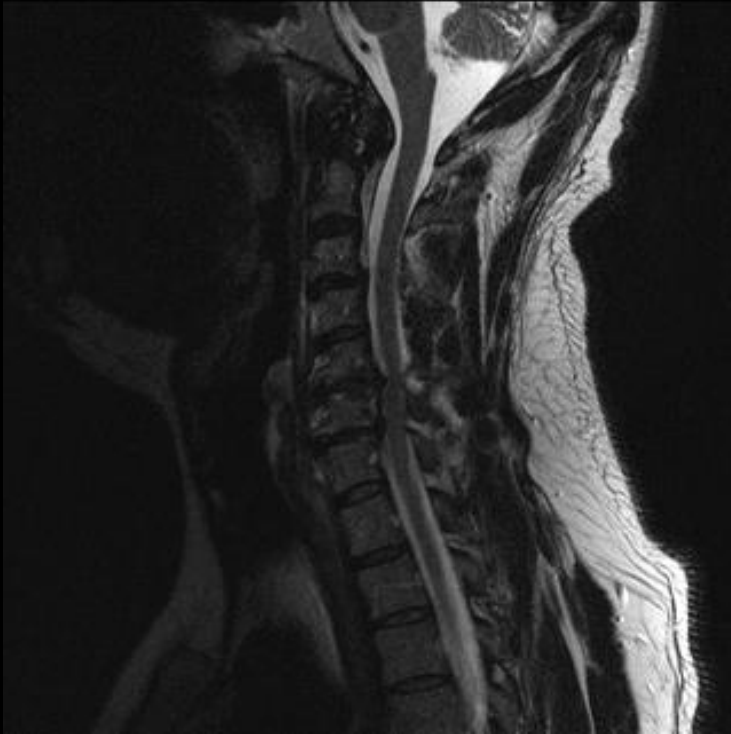Right C6 nerve root compression:

- Localized pain
- Local muscle spasms (multifidus and other)\* PROTECTION MECHANISM
- Radiating pain or other sensory complaints (axonal loss, conduction blocks, ephaptic transmission, etc.)
- Motor weakness

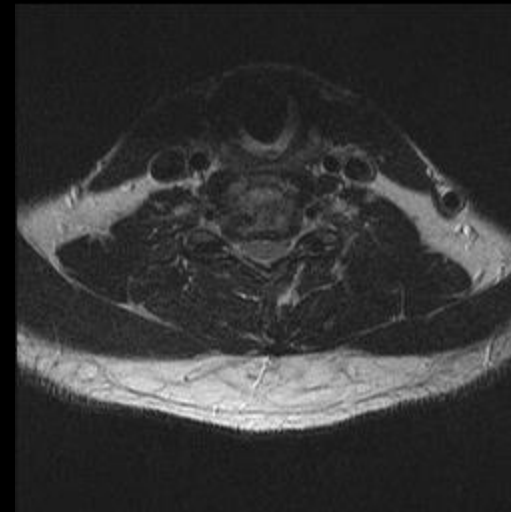


# Thoughts based upon MRI

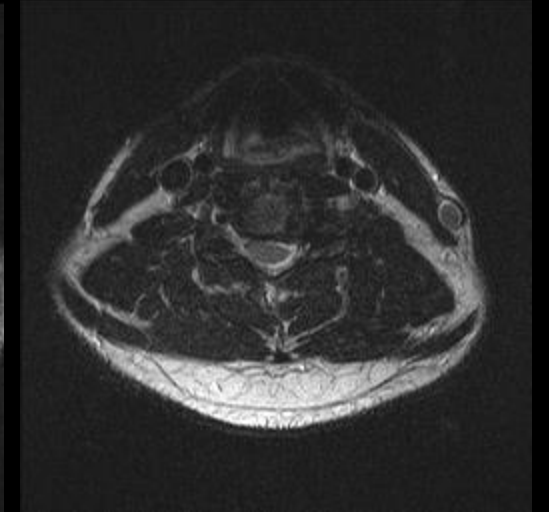
---



C4/C5



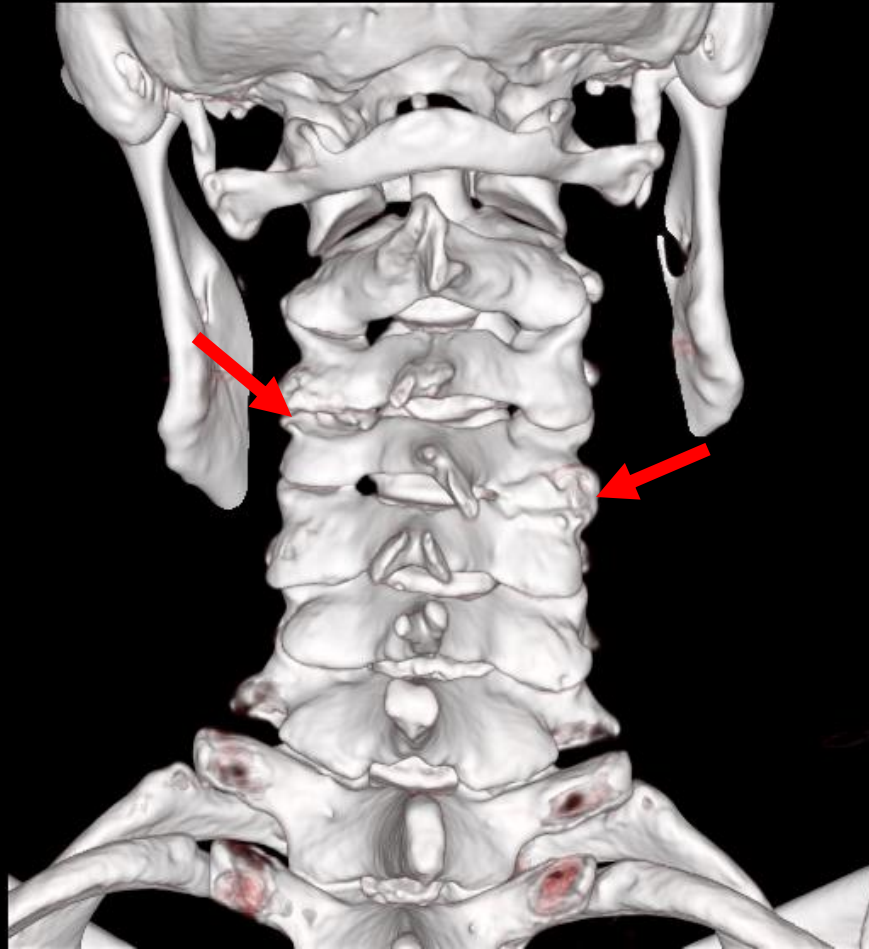
C5/C6



C6/C7

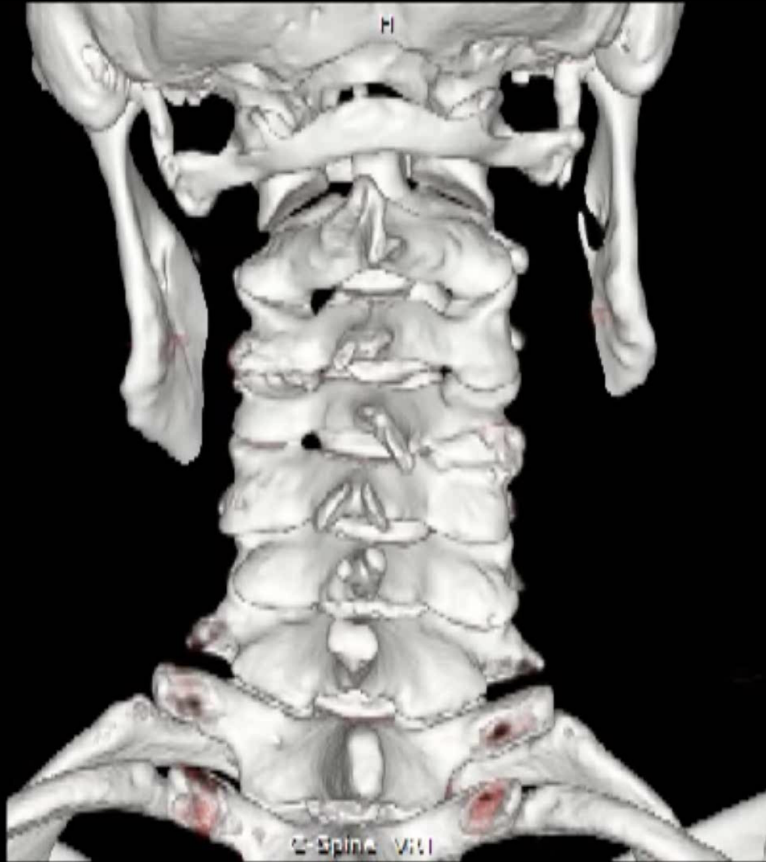# CT with 3D Rendering

---



# CT with 3D Rendering

---



# Axonal Loss and Double Crush Syndrome

---

- **The double crush in nerve entrapment syndromes**, Adrian Upton, Alan McComas, Lancet 1973. Aug 18;2(7825):359-62.
- Of 115 patients with entrapment, 70% had cervical lesion/proximal compression: predisposing the patients to entrapment neuropathy at a peripheral site.
- This is explained through interruption of axoplasmic transport
- Think “**Garden Hose Theory**”

# Axonal Loss and Double Crush Syndrome


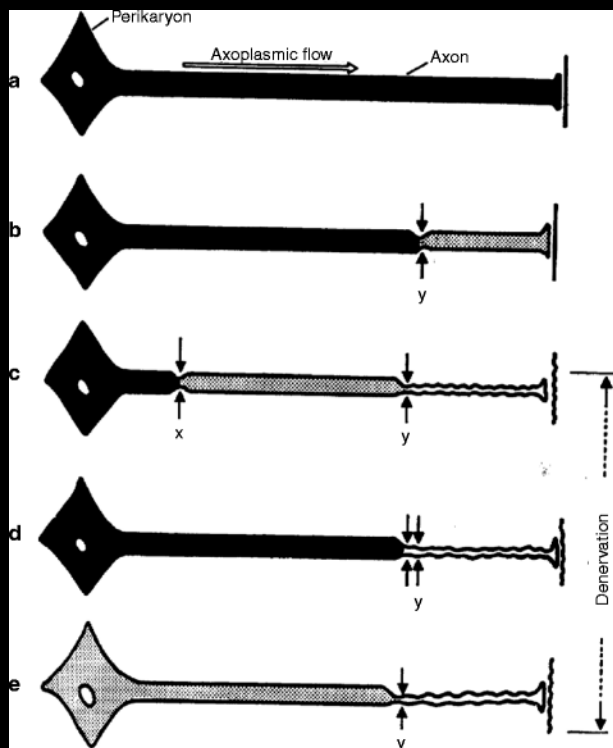
---

- This is explained through interruption of axoplasmic transport
- Think “**Garden Hose Theory**”



# Axonal Loss and Double Crush Syndrome

- This is explained through interruption of axoplasmic transport
- Think “**Garden Hose Theory**”



# Double Crush References

---

Upton AR, McComas AJ. **The double crush in nerve entrapment syndromes.** Lancet. 1973;2(7825):359–62.

Osterman AL. **The double crush syndrome.** Orthop Clin North Am. 1988;19(1):147–55.

Nemoto K, Matsumoto N, Tazaki K, Horiuchi Y, Uchinishi K, Mori Y. **An experimental study on the “double crush” hypothesis.** J Hand Surg. 1987;12(4):552–9.

Yao J, Osterman A. **Double crush syndrome.** Slutsky DJ, Hentz V, editors. Peripheral nerve surgery. Philadelphia: Churchill Livingstone/Elsevier; 2006. p. 277–83.

Dellon AL, Mackinnon SE, Seiler WA. **Susceptibility of the diabetic nerve to chronic compression.** Ann Plast Surg. 1988;20(2):117–9.

Wilbourn AJ, Gilliatt RW. **Double-crush syndrome: a critical analysis.** Neurology. 1997;49(1):21–9.

Morgan G, Wilbourn AJ. **Cervical radiculopathy and coexisting distal entrapment neuropathies: double-crush syndromes?** Neurology. 1998;50(1):78–83.

Novak CB, Mackinnon SE. **Multiple nerve entrapment syndromes in office workers.** Occup Med. 1999;14(1):39–59.

Wood VE, Biondi J. **Double-crush nerve compression in thoracic-outlet syndrome.** J Bone Joint Surg Am. 1990;72(1):85–7.

Carroll RE, Hurst LC. **The relationship of thoracic outlet syndrome and carpal tunnel syndrome.** Clin Orthop Relat Res. 1982;164:149–53.



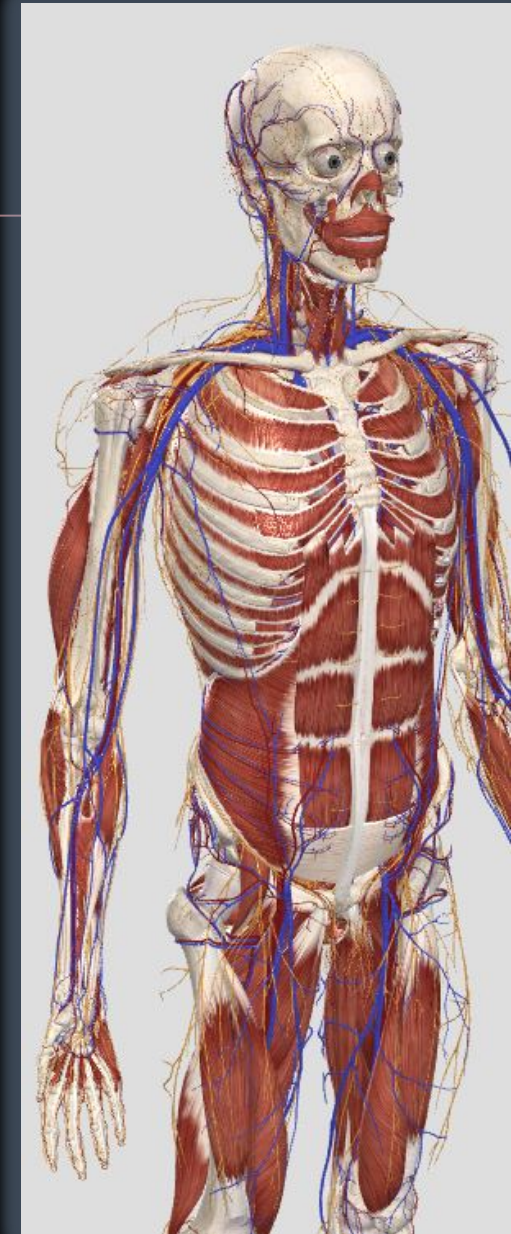
# Clinical Examination

What should the examination (at least cursory) include when evaluating for problems in the

- Hand
- Elbow
- Shoulder
- Neck

## Clinical Pearl:

Problem focused examinations risk overlooking a complicating or underlying pathology.



# Rotator Cuff Tears

---

**Prevalence of symptomatic and asymptomatic rotator cuff tears in the general population: From mass-screening in one village,** Hiroshi Minagawa,<sup>a</sup> et. al., J Orthop. 2013 Mar; 10(1): 8–12. Published online 2013 Feb 26. doi: [10.1016/j.jor.2013.01.008](https://doi.org/10.1016/j.jor.2013.01.008)

- The prevalence of rotator cuff tear in the **general population was 22.1%**, which increased with age (ages 2-80). Asymptomatic tear was twice as common as symptomatic tear.
- **Symptomatic** rotator cuff tears accounted for **34.7%** of all tears and **asymptomatic** tears for **65.3%**
- The prevalence of asymptomatic rotator cuff tears was one-half of all tears in the 50s, whereas it accounted for two-thirds of those over the age of 60.

# Rotator Cuff Tears

---

**Age-related prevalence of rotator cuff tears in asymptomatic shoulders**, Siegbert Tempelhof MD, Stefan Rupp MD, Romain Seil, MD, **Journal of Shoulder and Elbow Surgery**, Volume 8, Issue 4, July–August 1999, Pages 296-299, [https://doi.org/10.1016/S1058-2746\(99\)90148-9](https://doi.org/10.1016/S1058-2746(99)90148-9)

- Rotator cuff tears must to a certain extent be regarded as “normal” degenerative attrition, not necessarily causing pain and functional impairment.
- Incidence of Rotator Cuff tears (age related asymptomatic)
  - ages 50 to 59 - 13%
  - ages 60 to 69 - 20%
  - ages 70 to 79 - 31%
  - age >80 years - 51%

# Shoulder Pain

---

## ■ Common Conditions

- Degenerative Arthritis
- Rotator Cuff Tear
- Acromioclavicular Joint Pain
- Subdeltoid Bursitis
- Bicipital Tendonitis
- Supraspinatus Syndrome
- Deltoid Syndrome
- Scapulocostal Syndrome

## ■ Uncommon Conditions

- Suprascapular Nerve Entrapment
- Supraspinous Tendonitis
- Infraspinatus Tendonitis
- Subacromial Impingement Syndrome
- Os Acromiale Pain Syndrome
- Pectoralis Major Tear Syndrome
- Quadrilateral Space Syndrome

# Case Study - Patient C

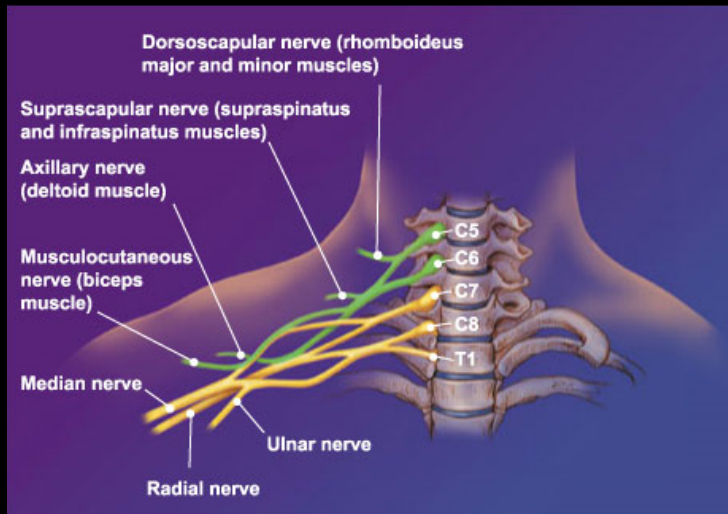
---

- 21 year old collage student with gradual onset of right shoulder pain, now reported as deep and aching and some perceived shoulder weakness. Pain is aggravated with certain shoulder and neck movements.
  - MRI Shoulder & C spine – Negative
  - EMG - CTS

# Case Study - Patient C

## Carpal Tunnel Syndrome

### ■ EMG - CTS

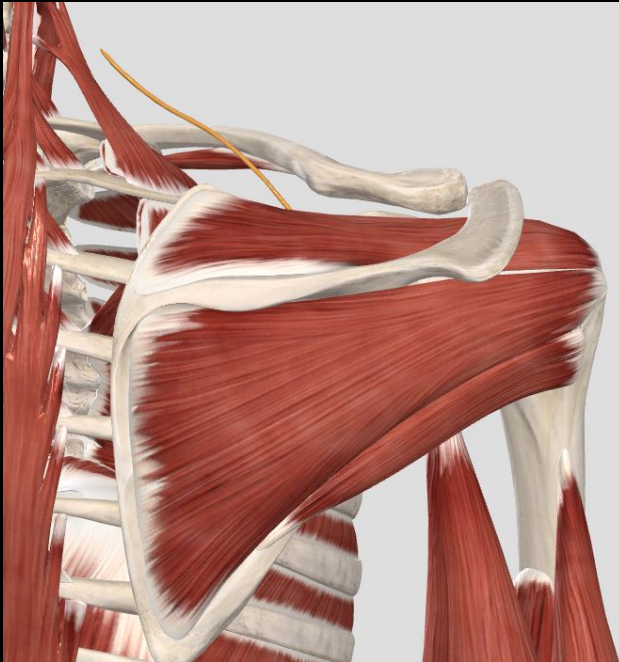


- The first dorsal interosseous
  - (an ulnar C8, T1 muscle)
- The flexor pollicis longus
  - (an anterior interosseous C7,8 muscle)
- The flexor carpi radialis
  - (a median C7 muscle)
- The brachioradialis
  - (a radial C5,6 muscle)
- The triceps
  - (a radial C7,8 muscle)
- The deltoid
  - (an axillary C5,6 muscle)
- Related Cervical Paraspinals

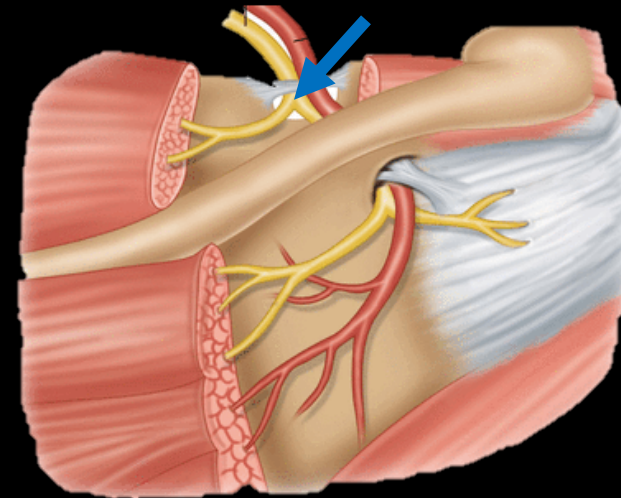
# Case Study - Patient C

---

Edx: EMG Supra/infraspinatus muscles, SEP of suprascapular nerve above and below bifurcation.



## Suprascapular nerve entrapment



# Clinical Pearls - EMGs

---

- Pre-ganglionic sensory radiculopathies cannot be identified by classic EMG/NCV.
- Cookie-cutter studies are very limited in their ability to identify pathology by being narrowly focused. In this regard, tailoring the study to the patient can significantly increase diagnostic yield.

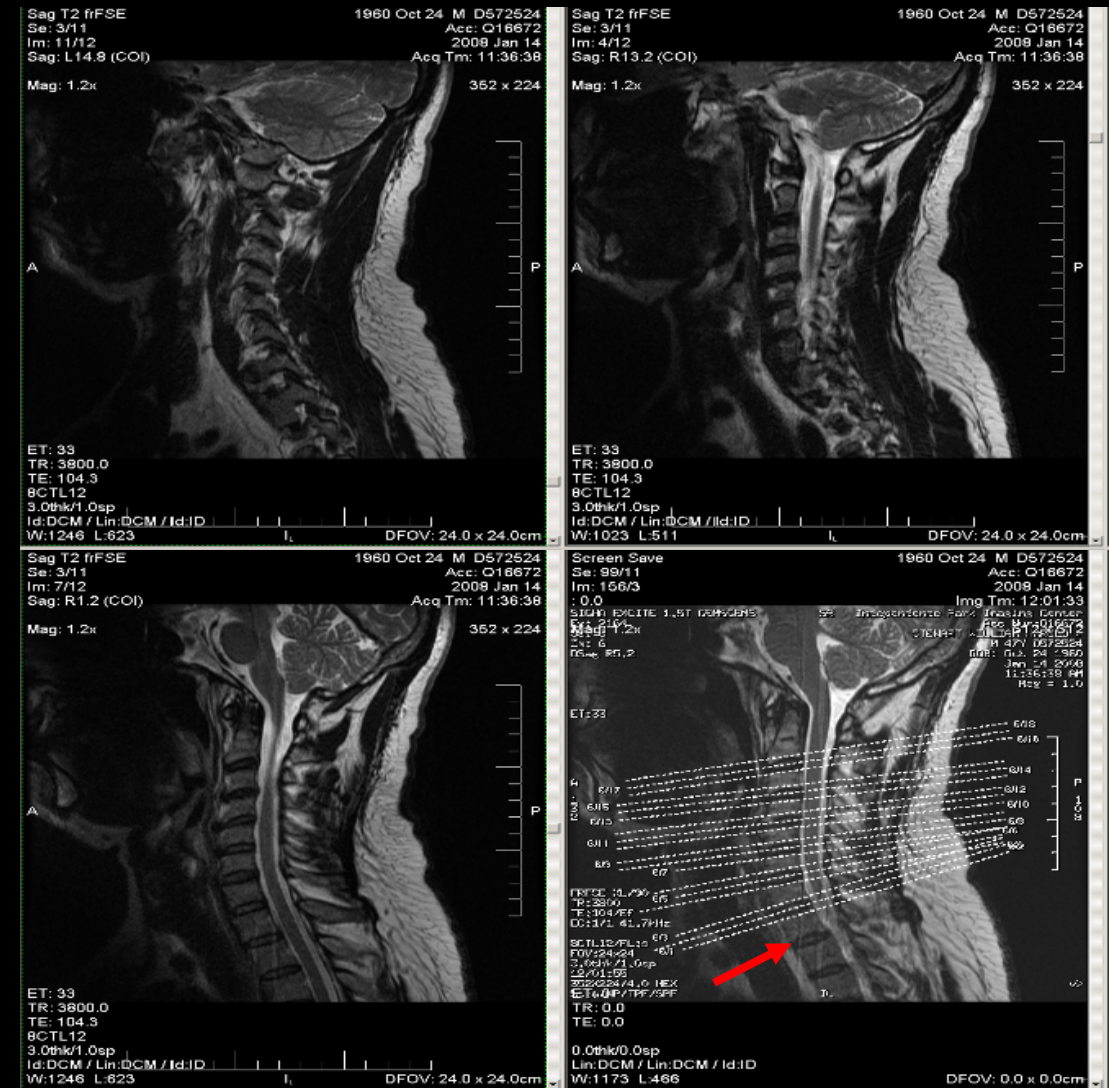
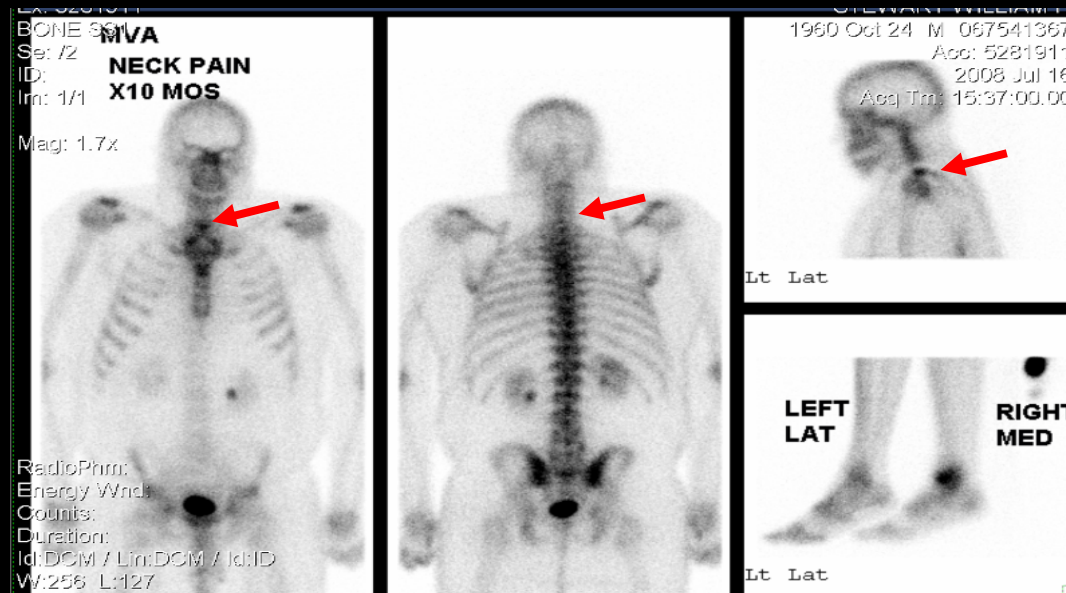

# Case Study - Patient D

---

- 47year old right handed male in significant distress and discomfort with respect to his cervical spine, complaining of neck pain accompanied with “shock-like” and “knife-like” shooting pains with seemingly the slightest movements.
- There is a constant the focal area of pain centralized to the mid-to-lower cervical spine.
- He complains of suboccipital headaches favoring the right side and radiates frontally that appears to be directly related to exacerbations of his neck pain.
- Other complaints include occasional tingling into the anterior medial right forearm and right upper extremity weakness.
- Onset six months prior while a front seat passenger in an MVA.

- **X-ray** – Unremarkable
- **MRI** – Mild DJD C3/C4, C4/C5
- **EMG** – Pt could not tolerate
- **SEP** – T1 Radiculitis
- **Bone Scan** – Inconclusive



# Take Home Message

---

- The reliability or the clinical relevance of any diagnostic procedure is never 100%.
- The studies themselves may be deficient in that particular clinical situation.
  - Inadequately structured for that particular patient.
  - Adversely effected by other influences (technical considerations).
- Objective clinical examination findings should not be dismissed based solely upon negative test results.
- Sometimes there is more than one pain generator.
- Look at the patient, not only a body part, giving careful thought to anatomy and physiology (or pathophysiology).