



Flow to the Toe: Differentiating Neurogenic and Vascular Claudication

Peter Pryzbylkowski, MD

Title & Affiliation

Peter Pryzbylowski, MD
Interventional Pain Specialist
Relievus Pain Management
Philadelphia, PA

Disclosure

- Consultant for VERTOS (MILD procedure)
- Consultant for NEVRO (spinal cord stimulator company)
- Consultant for Abbott (spinal cord stimulator company)

Learning Objectives

- Distinguish the differences on history and physical exam between neurogenic and vascular claudication
- Cite appropriate studies to order for vascular vs neurogenic claudication
- Review causes of neurogenic claudication
- Describe new treatment options for patients with lumbar spinal stenosis with neurogenic claudication

Curriculum Vitae

- Franklin and Marshall College
- Robert Wood Johnson Medical School
- University of Pennsylvania
 - Assistant Professor
- Private Practice
 - Relievus

Types of Claudication

	Vascular Claudication	Venous Claudication	Neurogenic Claudication
Quality of pain	Cramping	"Bursting"	Electric shock-like
Onset	Gradual, consistent	Gradual, can be immediate	Can be immediate, inconsistent
Relieved by	Standing still	Elevation of leg	Sitting down, bending forward
Location	Buttock, thigh, calf	Whole leg	Poorly localized, can affect whole leg
Legs affected	Usually one	One or both	Often bilateral

Unfortunately, history alone
can miss up to 90% of cases!

Peripheral Arterial Disease

- PAD occurs in approximately 1/3 of all patients
- Significant risk increases at age 50 and in smokers or DM
- Progressive disease in 25% with worsening claudication or limb threatening ischemia
- Increased risk of stroke, MI, and cardiovascular death
- Impaired quality of life, limb loss, and early mortality

Rule of 1/3s

- About 1/3 have classic symptoms
- About 1/3 have atypical symptoms
- About 1/3 have NO symptoms

Risk Factors

Smoking
Diabetes
Hypertension
Hypercholesterolemia
Hyperhomocysteinemia
Fibrinogen
C-reactive protein
Alcohol

Relative Risk

Reduced Increased

.5 1 2 3 4 5 6

Classification Systems

Fontaine		Rutherford		
Stage	Clinical	Grade	Category	Clinical
I	Asymptomatic	0	0	Asymptomatic
IIa	Mild claudication	I	1	Mild claudication
IIb	Moderate to severe claudication	I	2	Moderate claudication
		I	3	Severe claudication
III	Ischemic rest pain	II	4	Ischemic rest pain
IV	Ulceration or gangrene	III	5	Minor tissue loss
		III	6	Major tissue loss

Detecting PAD in Clinical Practice

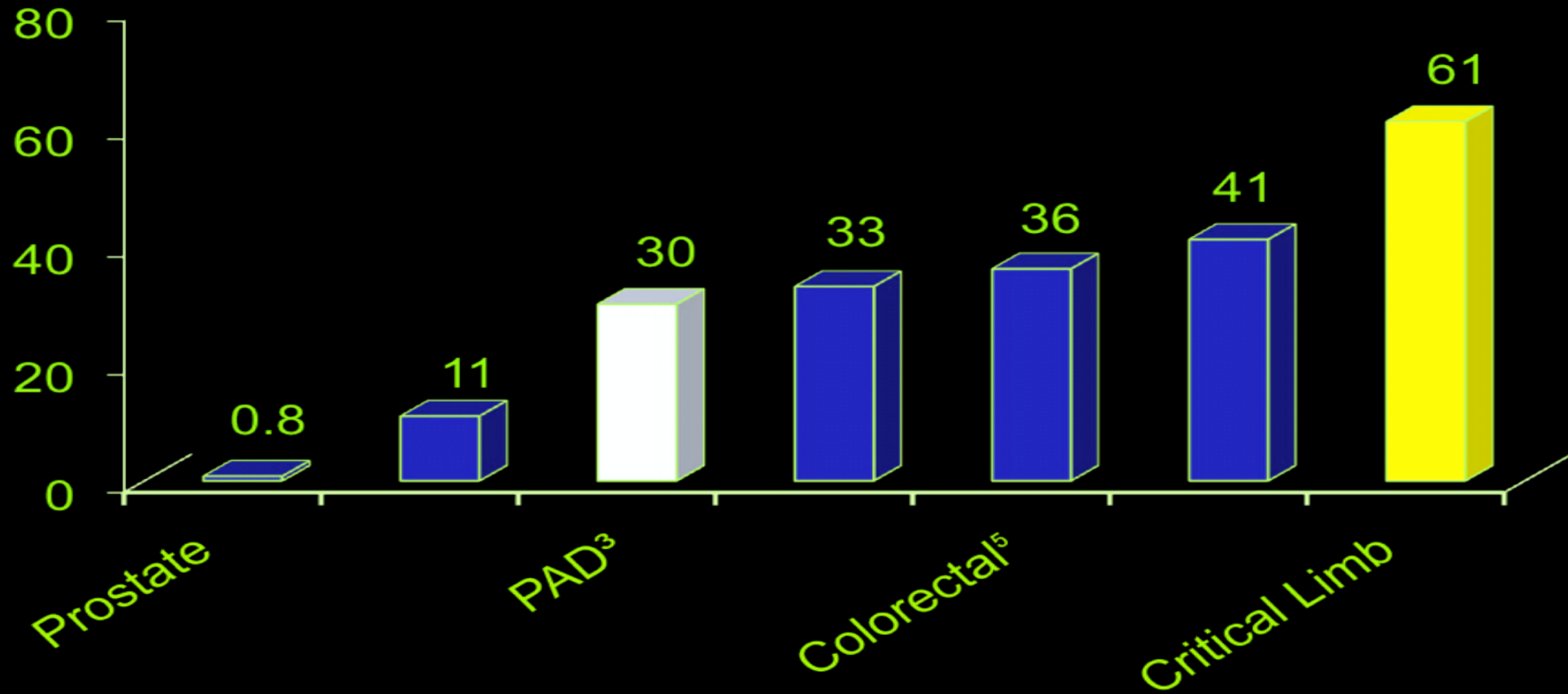
- Consider performing ABI testing for at risk population in office
- Consider questionnaire:
 - Slow healing wound or ulcers
 - Missing pulses or poor circulation
 - Exertional cramping or fatigue relieved by rest
 - Resting pain in extremity that may disturb sleep
 - Gangrenous or black skin tissue
 - Toes or feet that have become pale or discolored

Critical Limb Ischemia (CLI)

- Critical limb ischemia refers to a condition characterized by chronic ischemic at-rest pain, ulcers, or gangrene in one or both legs attributable to objectively proven arterial occlusive disease
- Prevalence is 1.5% of all patients over 50
- Will develop in approximately 10% of patients with known PAD over lifetime

[Mark R Nehler](#) , [Sue Duval](#) , [Lihong Diao](#) , Brian H Annex et al. Epidemiology of peripheral arterial disease and critical limb ischemia in an insured national population. Journal of Vascular Surgery . 2014 Sep;60(3):686-95

5 Year Mortality Rates PAD/CLI



1. <http://seer.cancer.gov/statfacts/html/prost.html>;

2. <http://seer.cancer.gov/statfacts/html/breast.html>

3. <http://seer.cancer.gov/statfacts/html/colorect.html>; 6. Hartmann A, Rundek T, Mast H, et al. Mortality and causes of death after first ischemic stroke: the Northern Manhattan Stroke Study. *Neurology*. 2001;57:2000-2005; 7. Conrad MF, et al *Journal of Vascular Surgery*, 2011, 53(4):1020-1025].

Treatment

- All patients with PAD
 - Immediate smoking cessation
(most beneficial modifiable risk factor)
 - Lipid control
 - Antiplatelet agents
 - Diabetes control
 - Blood pressure reduction

Statin Impact

- European REACH registry
 - 5,861 pts with symptomatic PAD
 - Pts on statin had a sig lower risk of the primary adverse limb outcome @ 4 yrs
 - 22.0 vs 26.2% ; HR 0.82; ; P = 0.0013.
 - Cardiac death/MI/CVA was also reduced
 - HR, 0.83; P = 0.01

Dharam J Kumbhani , Ph Gabriel Steg , Christopher P Cannon , Kim A Eagle et al. Statin therapy and long-term adverse limb outcomes in patients with peripheral artery disease: insights from the REACH registry
European Heart Journal. 2014 Nov 1;35(41):2864-72

In Practice

- ASA 81 mg daily OR clopidogrel 75 mg daily
- Tobacco cessation strategy
- Statin to lower LDL <70 mg/dL
- Blood pressure reduction - prefer an ACE-I target less than 130/85
- Target Hgb A1c < 6
- Claudication
 - Exercise prescription
 - Cilostazol 100 mg po BID (If no CHF) *
- Diabetes
 - Foot care/podiatry referral

Management of Symptomatic Patients

- Intermittent claudication pts without lifestyle limitation should undergo a trial of risk factor modification and exercise program
- Claudication pts with inflow disease or lifestyle limitation should be considered for revascularization
- Critical limb ischemia (rest pain or tissue loss) should undergo revascularization as soon as possible
 - AHA Level IA Recommendations

Multidisciplinary Approach

- Multidisciplinary foot care teams for non-healing wounds have been shown to reduce amputation rates from 36-86%
- The care provided by the disciplines should coordinate diagnosis, offloading, preventative care, and revascularization
- PCP, vascular specialist, podiatrist, wound care, infectious disease, endocrinologist, general surgeon

Sanders LJ, Robbins JM, Edmonds ME. History of the team approach to amputation prevention: pioneers and milestones. Journal of Vascular Surgery. 2010 Sep;52(3 Suppl):3S-16S.

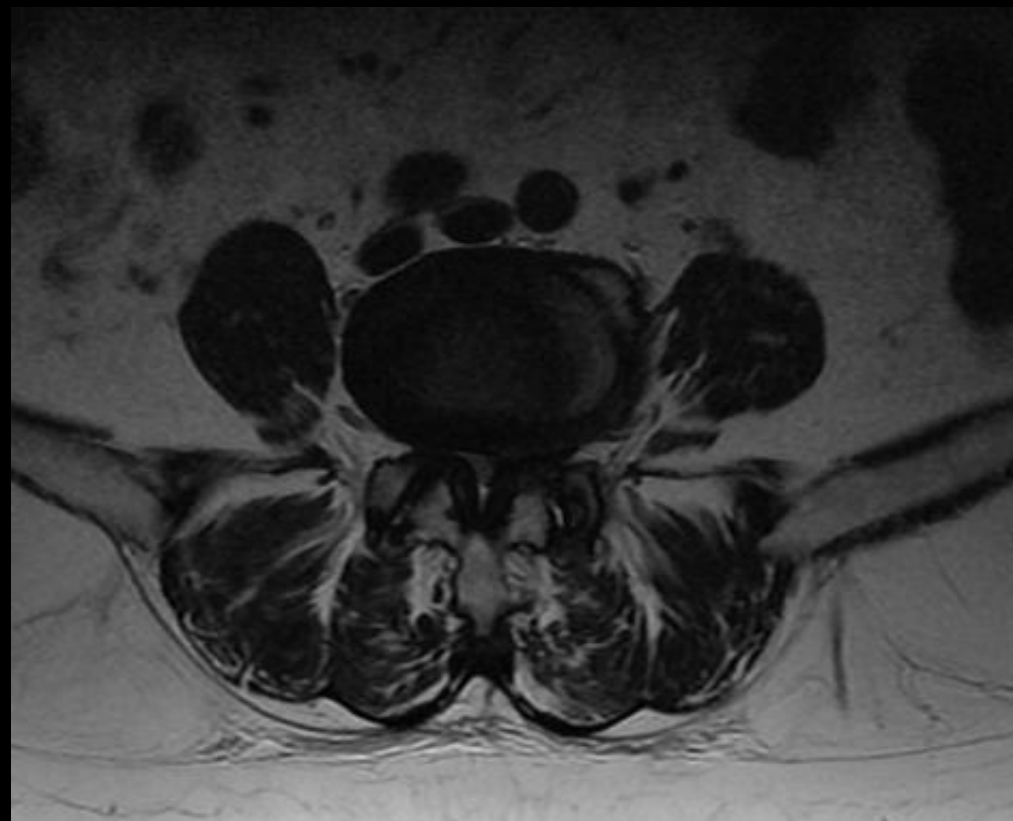
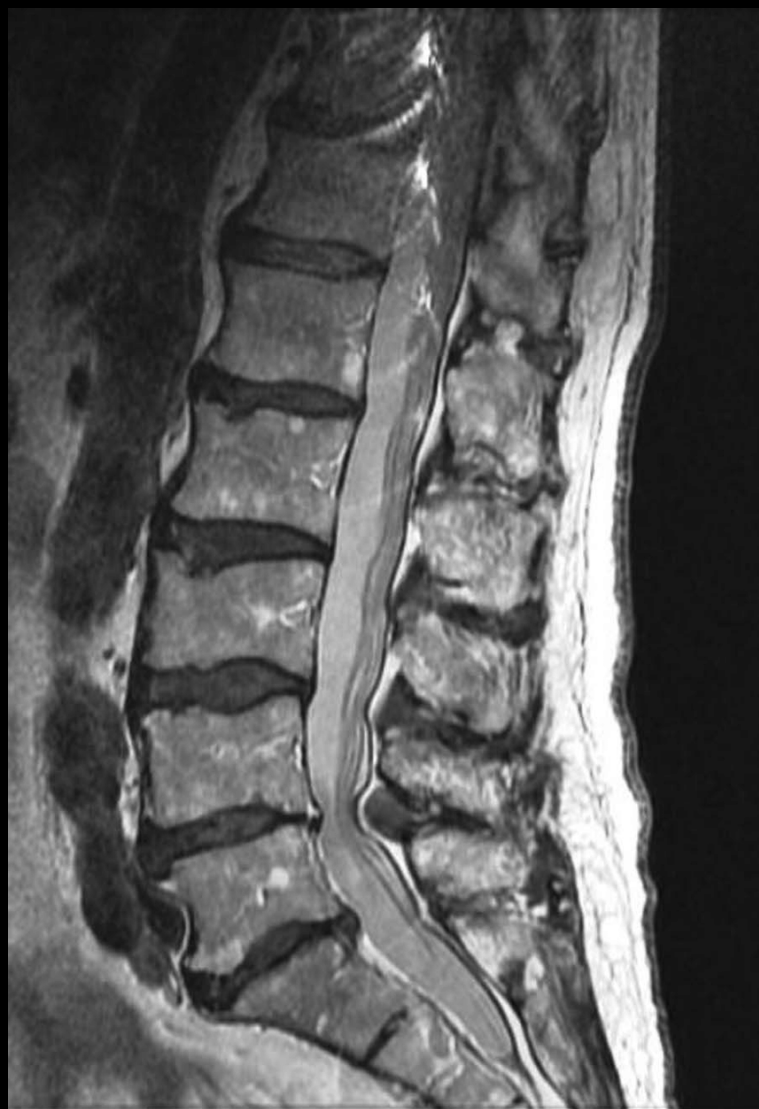Flow to the Toe: Differentiating Neurogenic and Vascular Claudication

Types of Claudication

	Vascular Claudication	Venous Claudication	Neurogenic Claudication
Quality of pain	Cramping	"Bursting"	Electric shock-like
Onset	Gradual, consistent	Gradual, can be immediate	Can be immediate, inconsistent
Relieved by	Standing still	Elevation of leg	Sitting down, bending forward
Location	Buttock, thigh, calf	Whole leg	Poorly localized, can affect whole leg
Legs affected	Usually one	One or both	Often Bilateral

Lumbar Spinal Stenosis

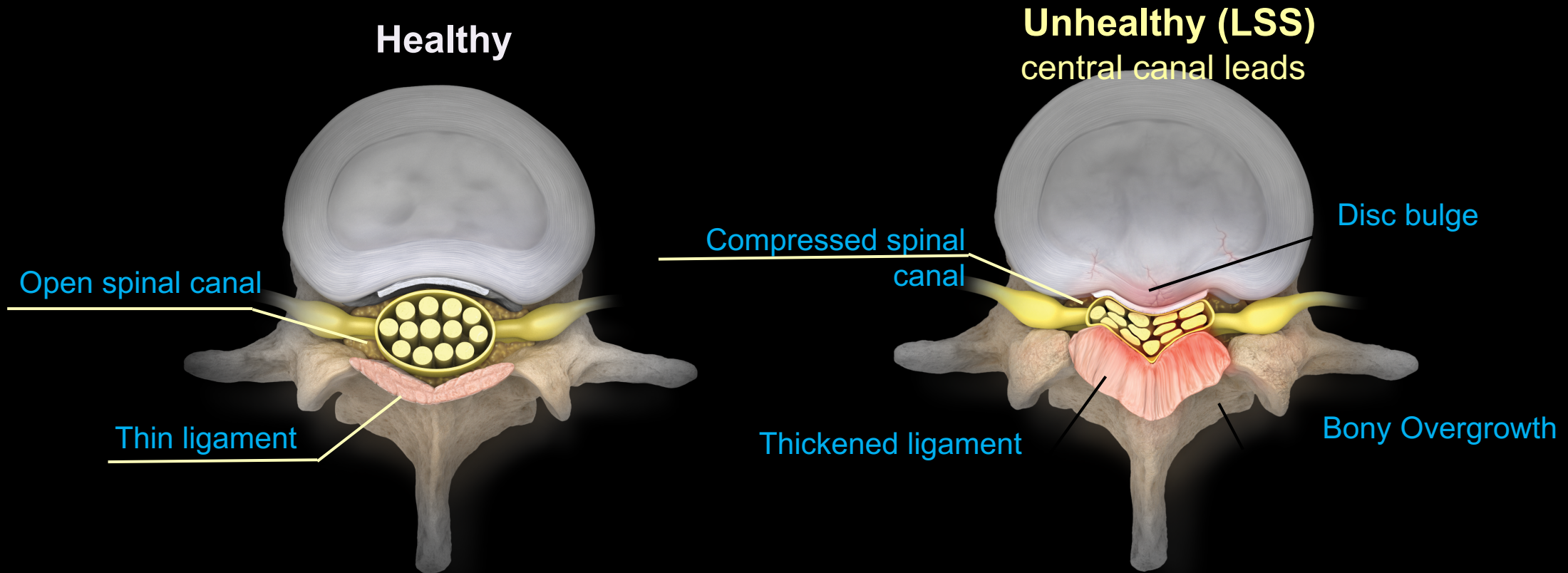
- Narrowing of the spinal canal as we age
- Normal degenerative process
- Treatment has improved over last 5 years
 - Typically series of lumbar epidural steroid injections
 - Laminectomy
 - Now have two newer treatment options
 - MILD procedure
 - Superion Interspinous Spacer Insertion



Lumbar Spinal Stenosis Signs/Symptoms

- Pain in back and legs that is worse with standing/walking
- Better with lumbar flexion
- Can be associated with numbness/tingling and/or weakness in legs

Lumbar Spinal Stenosis (LSS)

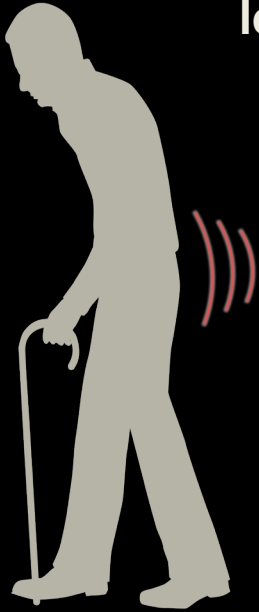


Degenerative changes causing spinal canal narrowing

Stenosis in Greek means “choking”

Identifying Neurogenic Claudication

Limited functionality is a key indicator of neurogenic claudication. It is important to ask your patients questions related to functionality rather than pain level to confirm symptomology.



Pain, numbness, or weakness PRESENT when standing or walking (extension)



Pain, numbness, or weakness RELIEVED when sitting or bending (flexion)

- ✓ Where do you experience discomfort?
- ✓ Does sitting or bending forward relieve your pain?
- ✓ How long can you stand/walk before you need to rest?

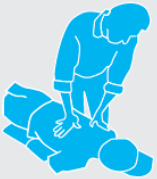“Shopping Cart Sign”



When Epidurals Fail

Low Risk – Least Aggressive

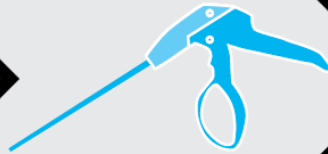Higher Risk – More Aggressive



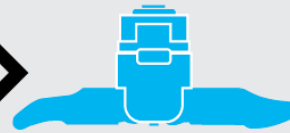PT
Meds



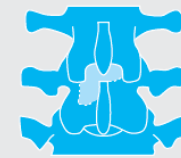ESI



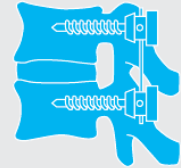
mild



Interspinous Process
Distraction Devices



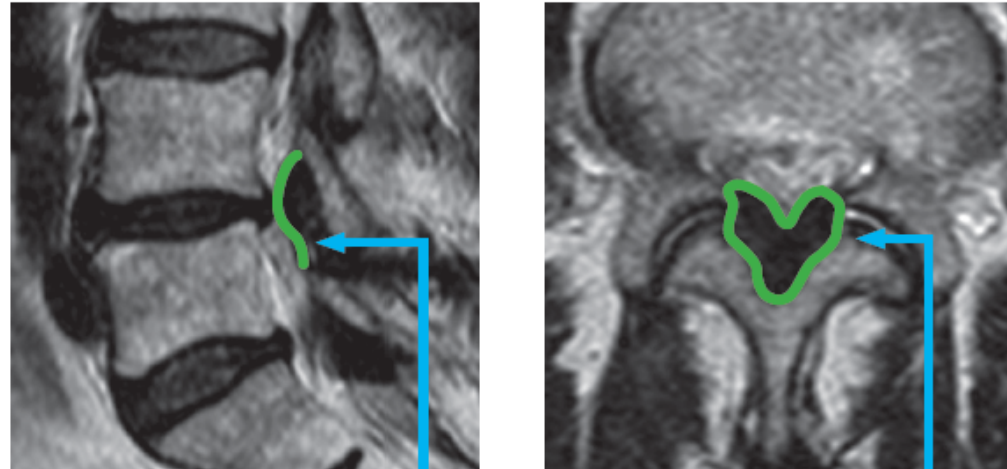
Open Laminotomy
Open Laminectomy



Fusion

Hypertrophic Ligamentum Flavum (HLF)

NC symptoms are caused by hypertrophic ligamentum flavum, which contributes to 50%-85% of spinal canal narrowing.



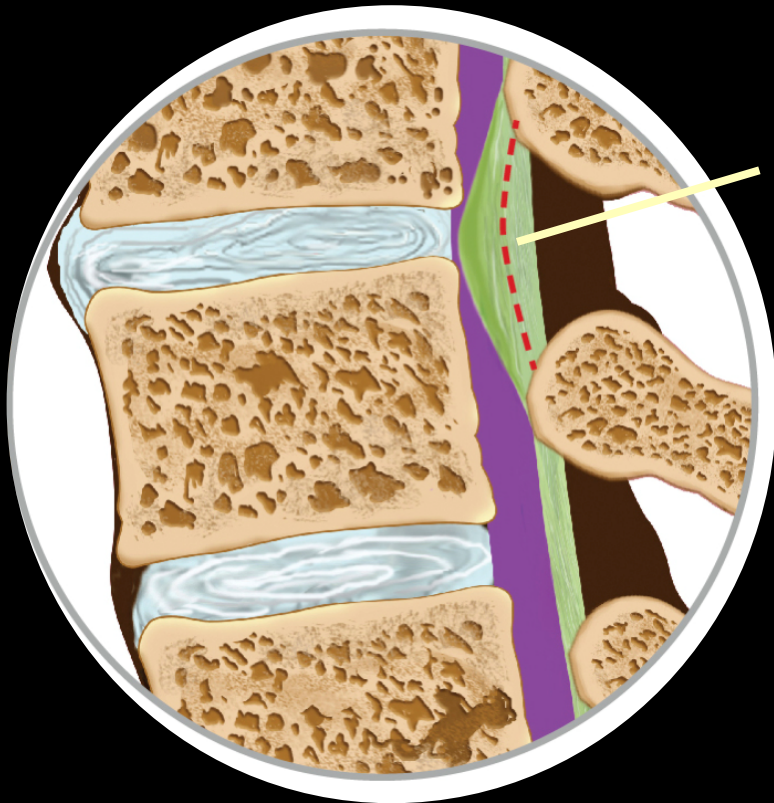
The overall reduction of spinal canal pressure from debulking the ligament has been shown to treat multifactorial etiologies

Removes the Problem, Leaves Nothing Behind

Percutaneous decompression is a safe, outpatient procedure that relieves pressure in the spinal canal by removing the excess ligament.

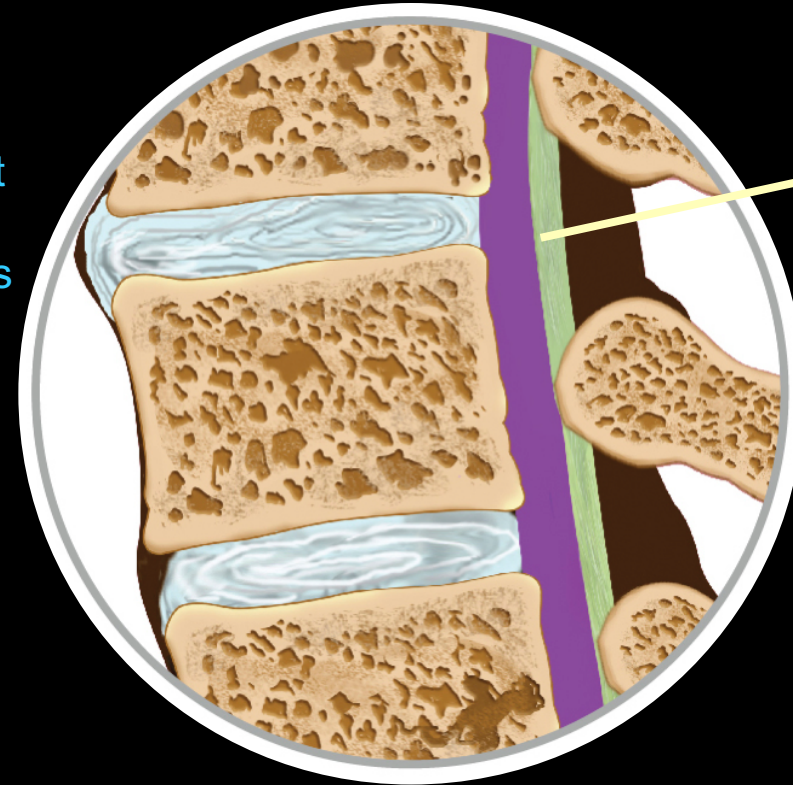
“It’s like removing a kink in a straw”

Before



- Thickened ligament
- Choking of canal
- Pain and numbness
- Reduced function

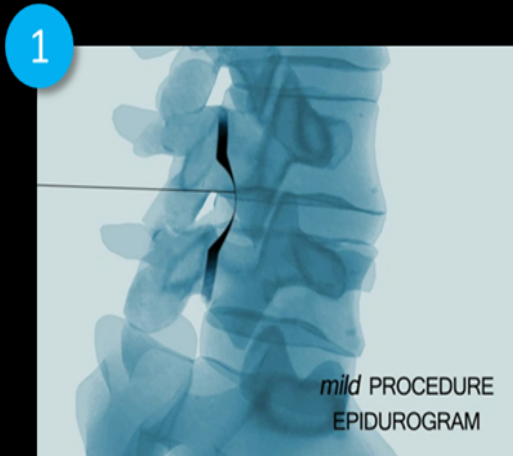
After



- Thinned ligament
- Space restored
- Pain relief
- Renewed mobility

Procedure Overview

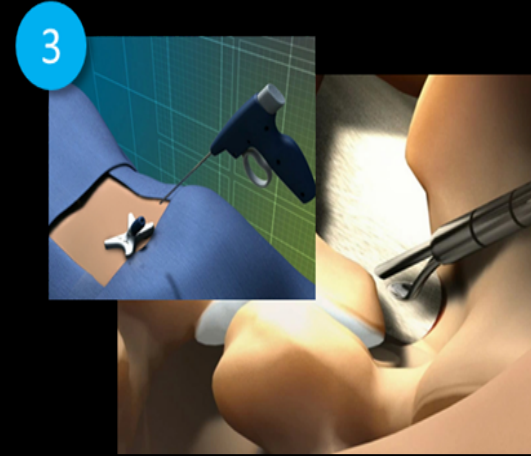
Physician simply removes bone and tissue using an epidurogram for visualization.
No implants, stitches, general anesthesia, or overnight hospital stay required.



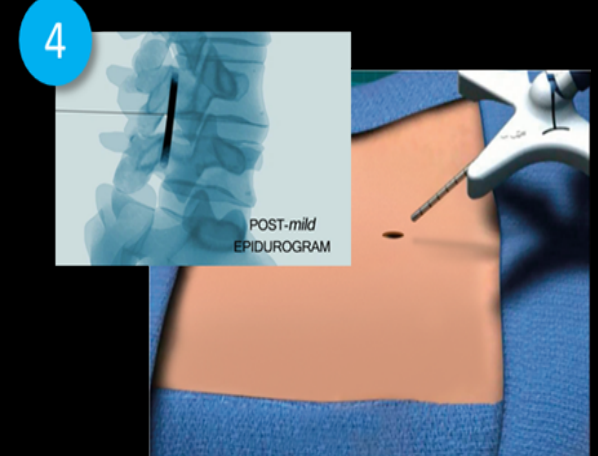
Perform
epidurogram to
visualize procedure



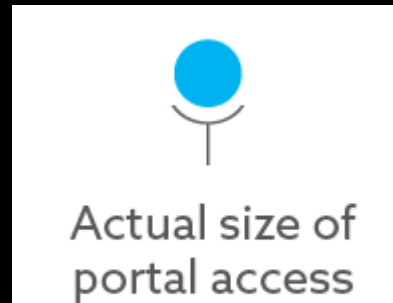
Create 5.1mm
treatment portal



Decompress ligament
using proprietary
instrumentation

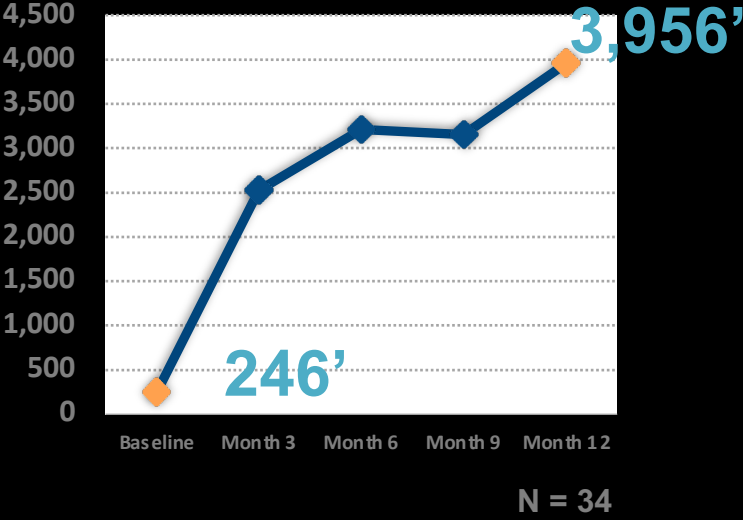

Remove devices &
close with Steri-strip

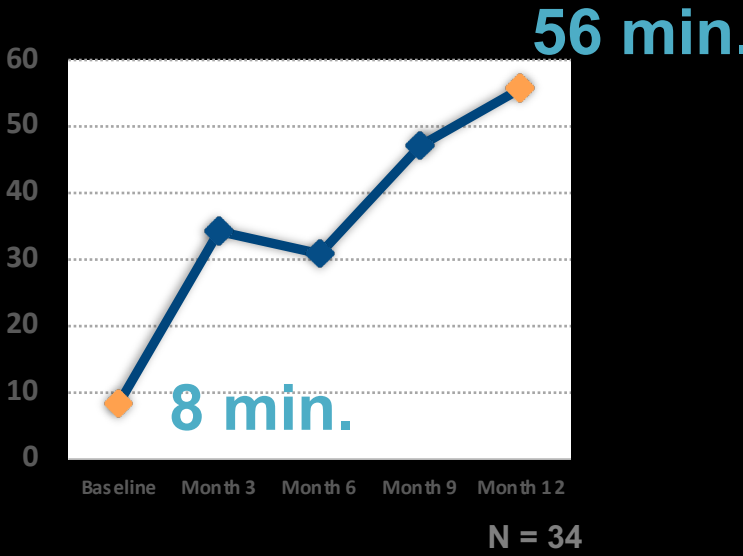


Outcomes

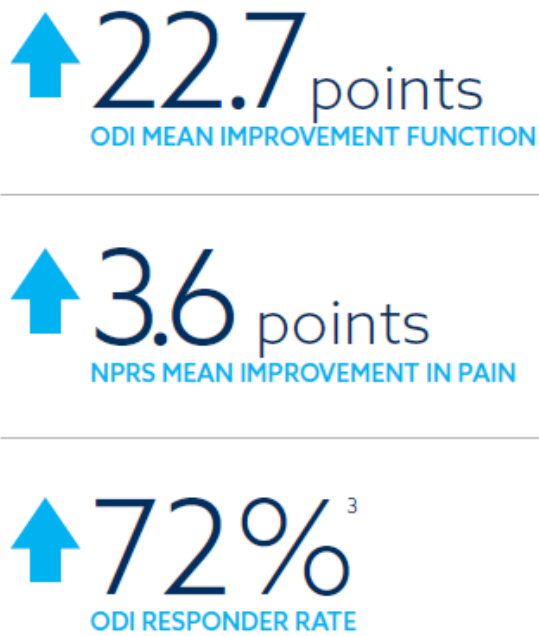
Walking



Standing



Cleveland Clinic Study
1 Year Outcomes



MIDAS ENCORE Study
2 Year Outcomes

[Ramsin M Benyamin](#), [Peter S Staats](#) et al. MILD® Is an Effective Treatment for Lumbar Spinal Stenosis with Neurogenic Claudication: MiDAS ENCORE Randomized Controlled Trial. Pain Physician. May 2016;19(4):229-42

[Nagy Mekhail](#), [Shrif Costandi](#), [Benjamin Abraham](#), [Samuel Wadie Samuel](#). Functional and patient-reported outcomes in symptomatic lumbar spinal stenosis following percutaneous decompression. Pain Practice. July 2012; 12(6):417-25

Patient History Pre-*mild*



77-YEAR-OLD FEMALE

- MEDICAL HISTORY: Hypertension, Afib, Asthma, GERD
- SURGICAL HISTORY: Colon resection, lumbar hemilaminectomy at right L4–L5
- SOCIAL HISTORY: Negative x 3
- ALLERGIES: Omnicef, Keflex
- MEDICATIONS:
Benazepril 10 mg QD, Cardizem 30 mg QD, Dexilant 60 mg QD, Flomax 0.4 mg QD, Xarelto 20 mg QD, Xyzal 5 mg QD prn, Tramadol 50 mg QD prn, Mobic 15 mg QD PRN



JUNE 2017

- 5-year history of **ESIs** from another local pain doctor
- Back pain VAS **9/10** with radiation to bilateral buttocks, right hip, right leg
- Treated with **4** right sacroiliac joint **injections** and **1** right GTB **injection** in my group

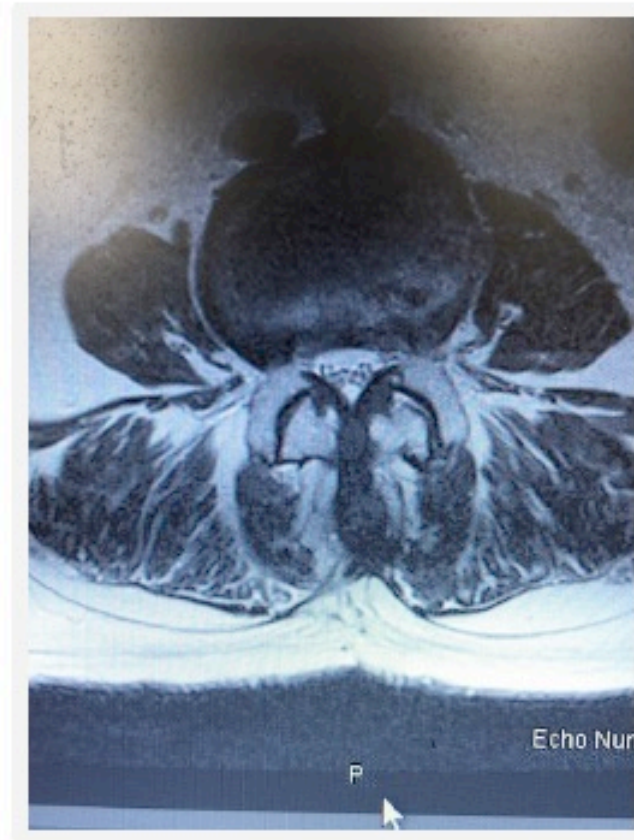
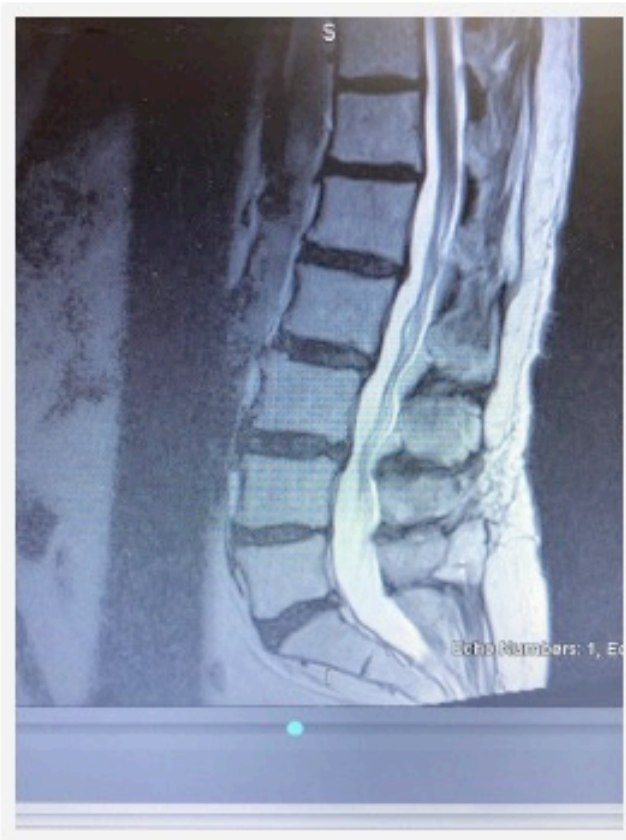
NOVEMBER 2018

(after ~1.5 years in group)

- Back pain VAS **6/10** with radiation to right hip and lateral aspect of right lower extremity
- Symptoms of neurogenic claudication: **Unable to stand or walk for >5 minutes**; discomfort relieved with sitting or flexion
- MRI confirmed LSS with HLF
- SCS or *mild*?

MRI Imaging

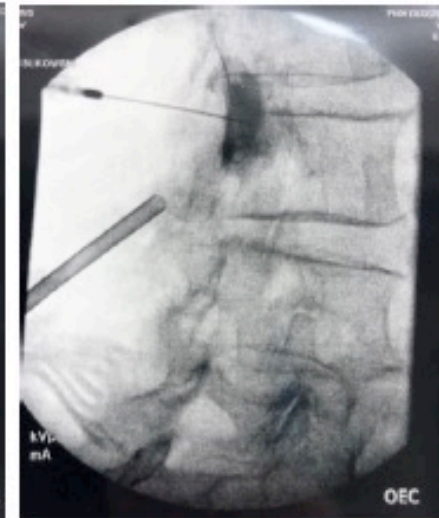
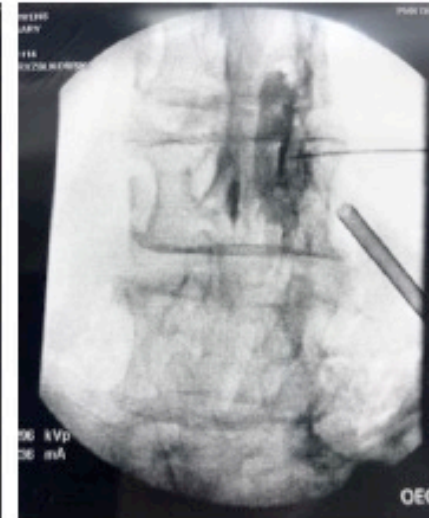
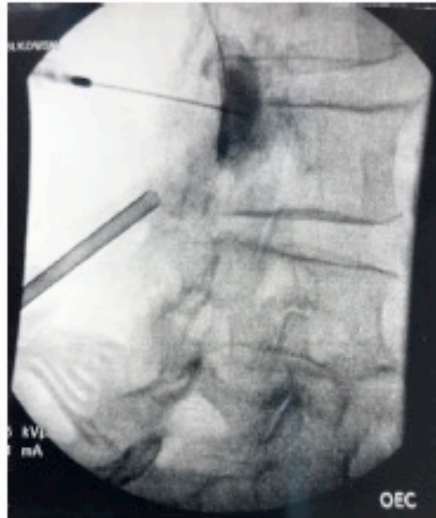
mild Procedure



PROCEDURE DETAILS

- PERFORMED: 12/19/18
- LEVELS TREATED: L3–L4, bilateral
- DURATION: 30-minute procedure from incision to closure




Choose *mild*



BEFORE *mild*

6/9/17



VAS 9/10



ABLE TO STAND/WALK:
< 5 minutes




5-year history of **ESIs**: 4 right
sacroiliac joint **injections**
and 1 right GTB **injection**



QOL: Poor

2 WEEKS POST-OP

1/4/19



VAS 0/10



ABLE TO STAND/WALK:
10 minutes

6 WEEKS POST-OP 15 WEEKS POST-OP

2/1/19

4/4/19



VAS 0/10



ABLE TO STAND/WALK:
25 minutes

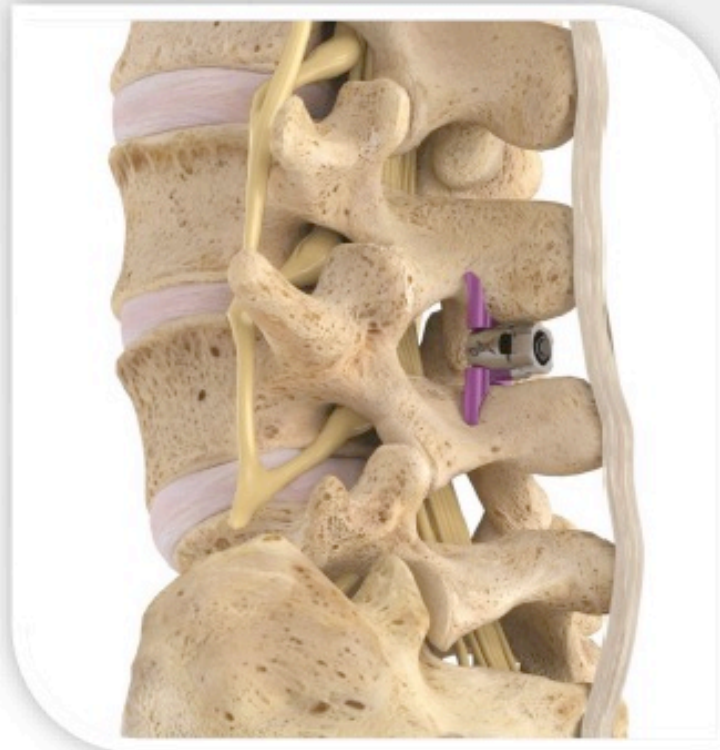

MEDS: Off all PRN
Tramadol and Mobic



QOL: Significant
improvement

Evidence-Based Therapy for the Treatment of Lumbar Spinal Stenosis

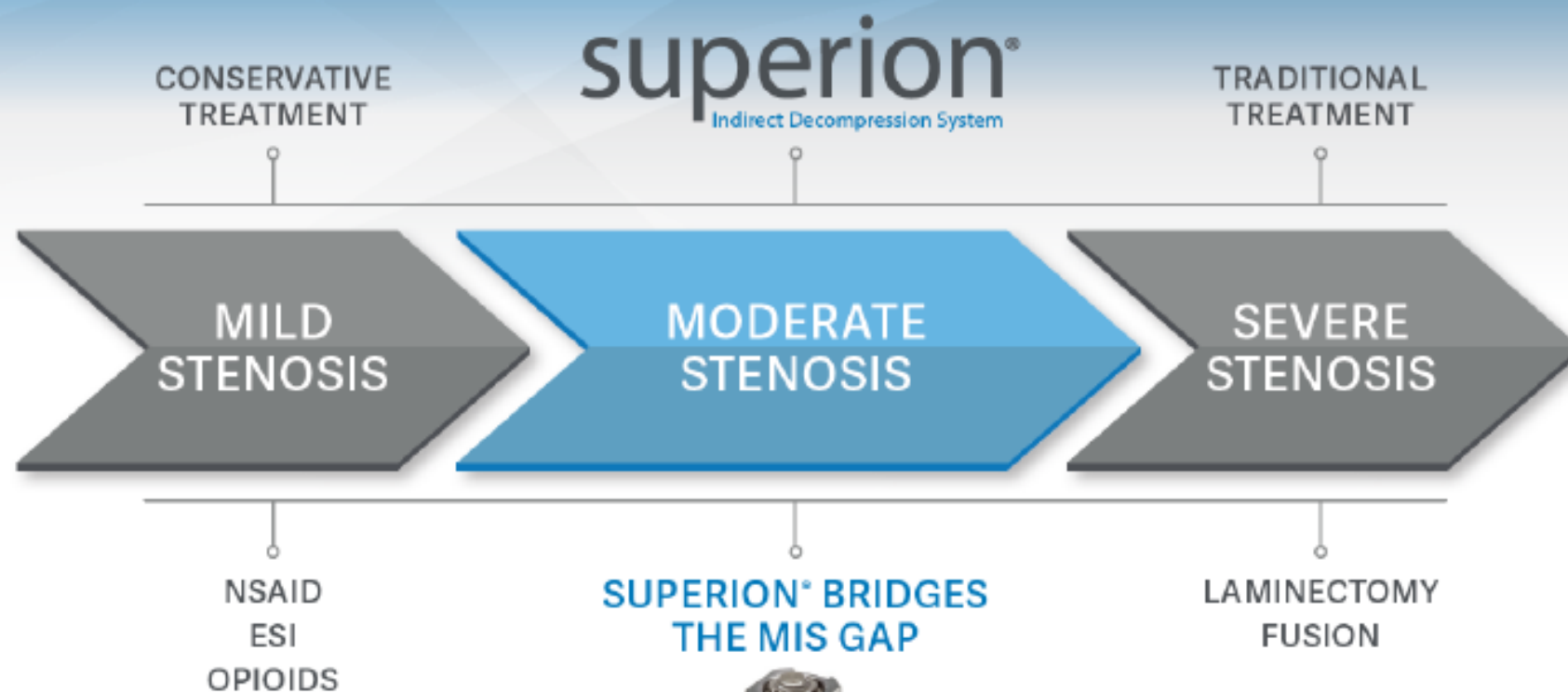

superion[®]
Indirect Decompression System

0184-A

©2018 Vertiflex, Inc. All rights reserved.

Lumbar Spinal Stenosis Continuum of Care



- ✓ Non-surgical patient; retains virgin back
- ✓ Treats central canal, lateral recess, and foraminal stenosis

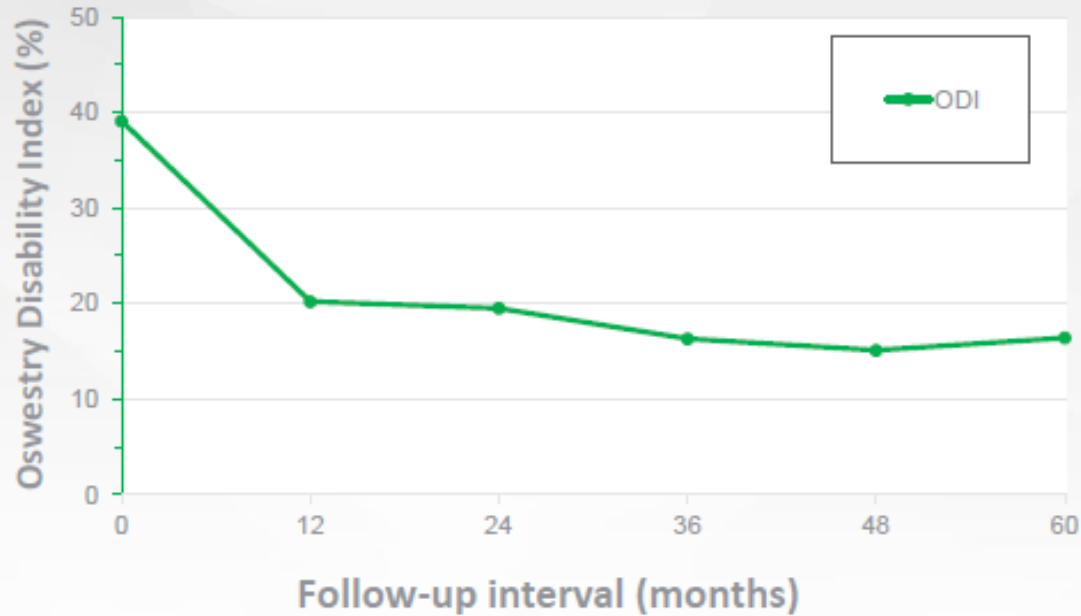
Superion US IDE Clinical Trial

Largest & Most Extensive Stenosis Device IDE Trial



Patel VV, Whang PG, Haley TR, Bradley WD, Nunley PD, Davis RP et al. Superior interspinous process spacer for intermittent neurogenic claudication secondary to moderate lumbar spinal stenosis: two-year results from a randomized controlled FDA-IDE pivotal trial. Spine. March 2015. 1;40(5):275-82

Oswestry Disability Index



Time course of results for the Oswestry Disability Index.
Note: Results reported as mean (95% CI).

>50%
improvement
in scores
from baseline
at 5 years

Clinical Interventions in Aging

8 pages ahead of the literature

Dovepress
open access to scholarly and medical research

ORIGINAL RESEARCH

Five-year durability of stand-alone interspinous
process decompression for lumbar spinal stenosis

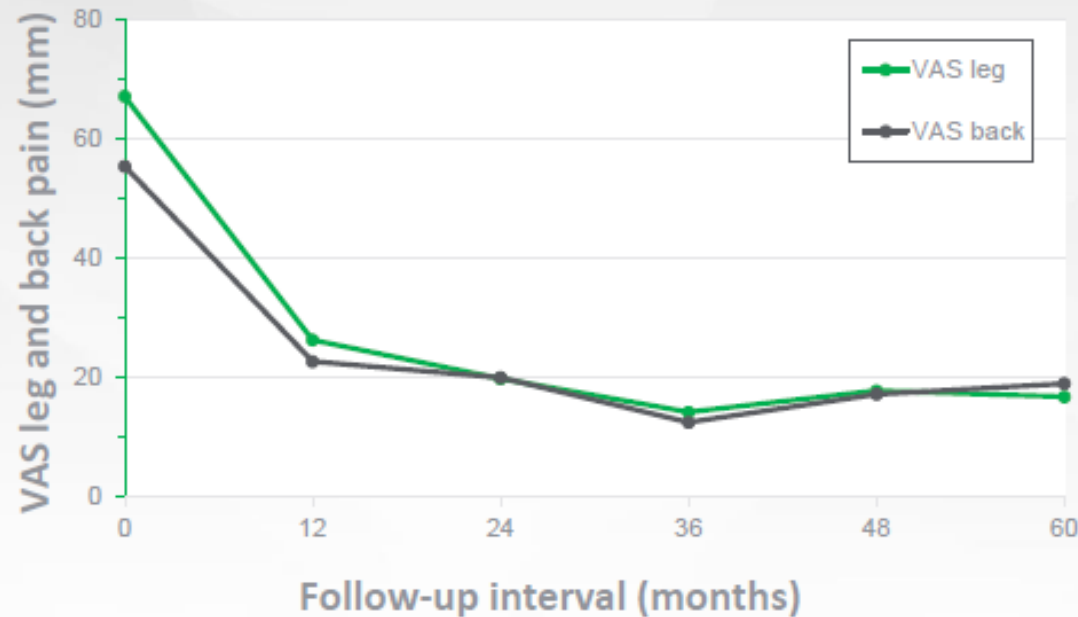
This article was published in the following Dove Press journal:
Clinical Interventions in Aging
9 September 2017
Check for updates at doi:10.1155/2017/1155201

VF-LD-0184-A

©2018 Vertiflex, Inc. All rights reserved

Patel VV, Whang PG, Haley TR, Bradley WD, Nunley PD, Davis RP et al. Superior interspinous process spacer for intermittent neurogenic claudication secondary to moderate lumbar spinal stenosis: two-year results from a randomized controlled FDA-IDE pivotal trial. Spine. March 2015. 1;40(5):275-82

VAS Leg & Back Pain



Time course of results for leg and back pain severity by VAS

Note: Results reported as mean (95% CI).

Abbreviation: VAS, visual analog scale.

75%
improvement
in leg pain
scores from
baseline at 5
years

Clinical Interventions in Aging

Dovepress

Open Access to Scientific and Medical Research

8 pages, 1000 words, 10 minutes

ORIGINAL RESEARCH

Five-year durability of stand-alone interspinous process decompression for lumbar spinal stenosis

This article was published in the following Dove Press journal:
Clinical Interventions in Aging
4 September 2017
(Number of views: 100, article has been viewed)

VF-LD-0184-A

©2018 Vertiflex, Inc. All rights reserved.

5 Year Efficacy and Durability

Superior Clinically Successful in Each Category

Responder Success at	2 years	3 Years	4 Years	5 Years
ZCQ Physical Function	72.5%	79.6%	80.0%	80.7%
ZCQ Symptom Severity	77.1%	84.3%	83.4%	75.0%
ZCQ Patient Satisfaction	84.0%	91.7%	86.7%	89.8%
ODI	63.4%	67.6%	61.1%	64.8%
VAS – Back Pain	67.2%	76.6%	66.7%	64.7%
VAS – Leg Pain	75.6%	82.8%	78.2%	80.0%
No Reoperations No Revisions	80.0%	78.4%	75.3%	74.7%

- SP fractures: 16% - Majority asymptomatic, and did not affect efficacy outcomes
 - Rate of fracture in commercial use: <1%
- No migrations & no dislodgements throughout the IDE trial and commercialization

Clinical Summary

- **BENEFITS OF SUPERION**

- Less invasive/traumatic approach; no anatomical “burned bridges” which may compromise future surgical treatment options
- Fewer/lesser post-operative complications
- Treats central, lateral recess, *and* foraminal stenosis
- Durable clinical benefit through 24, 36, 48, and 60 months

- **RISKS**

- Reoperation rate (>75% of patients did not require a re-operation)
- Spinous process fracture (majority asymptomatic; 32% healing rate at 24 months, 55% at 60 months; no impact upon outcomes)

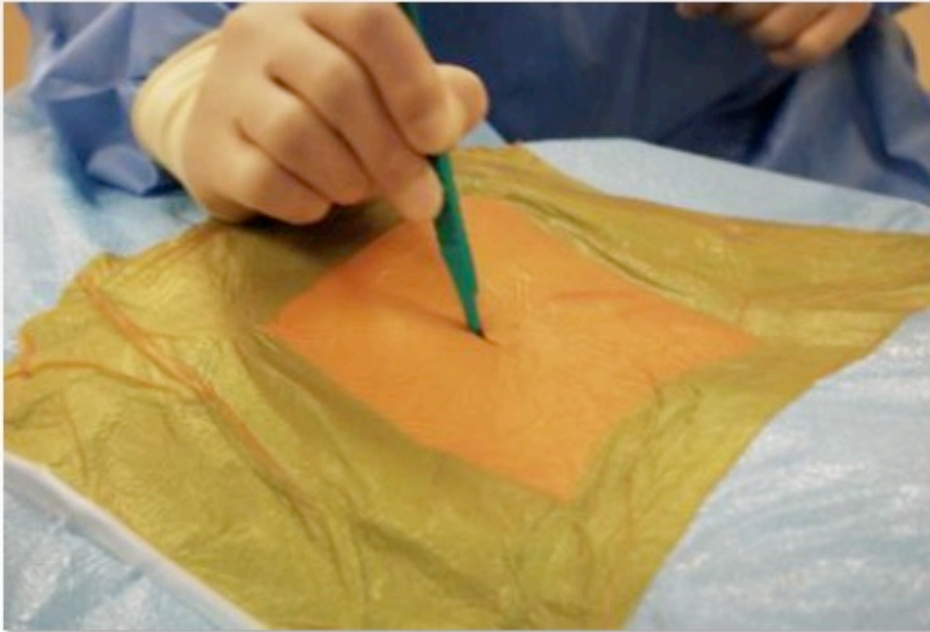
- **RISK MITIGATION**

- Labeling disclosures identify and mitigate risks
- Physician training to optimize patient selection and technique



Skin Incision

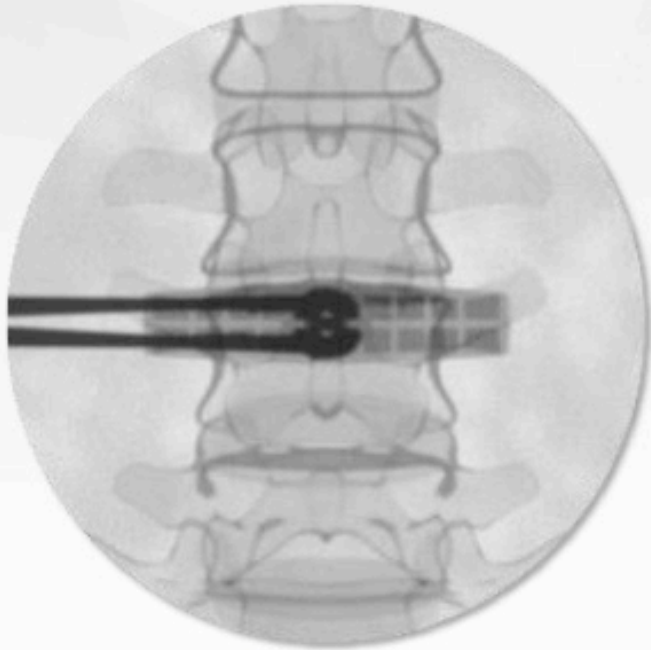
- Make a 12-15mm incision at the operative level to expose the supraspinous ligament (SSL).



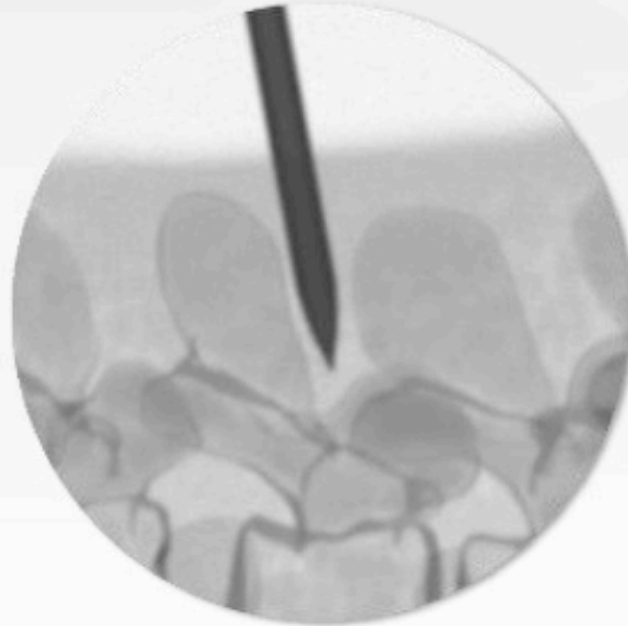
VF-LD-0184-A

©2018 Vertiflex, Inc. All rights reserved

Insertion of Dilator



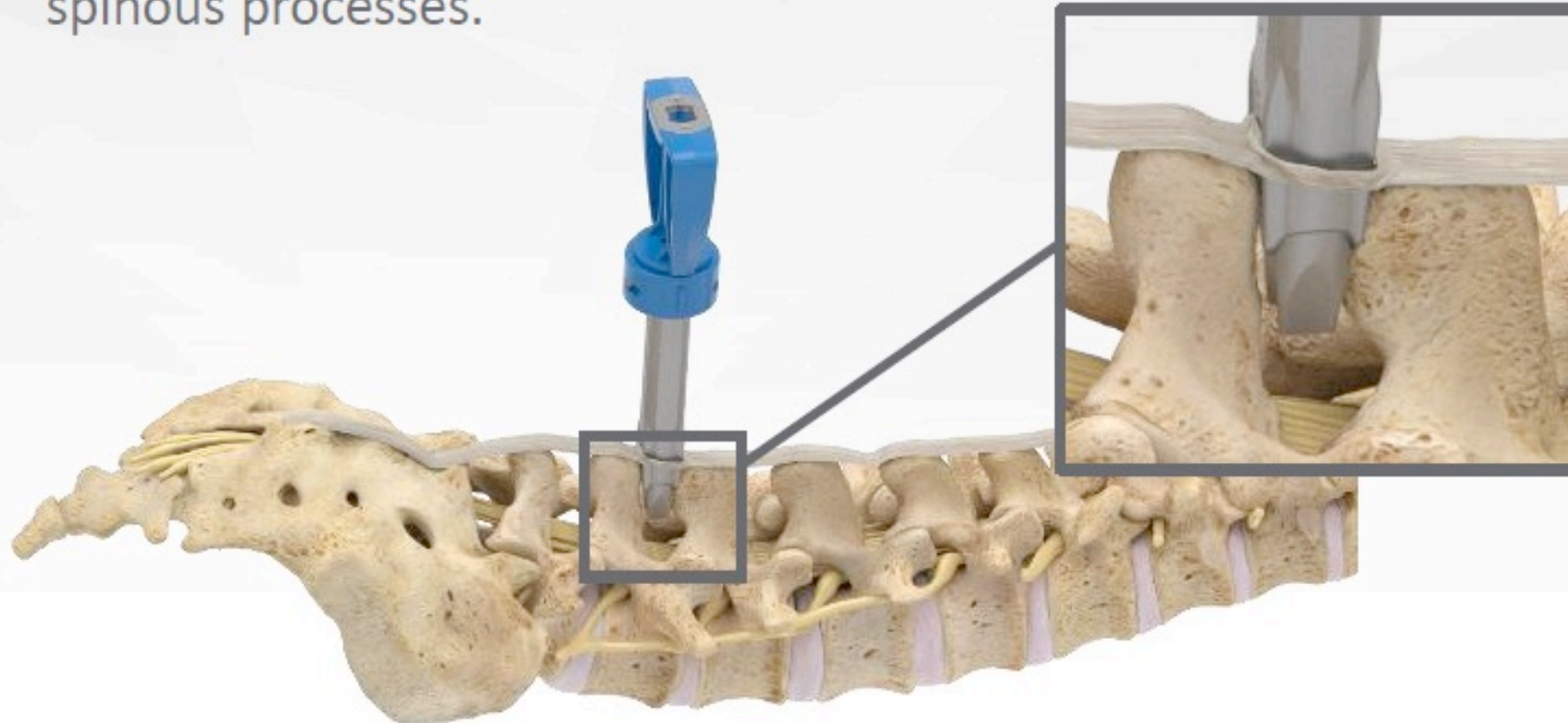
A/P View:
Dilator Position



Lateral View:
Dilator Position

Insertion of Cannula Assembly

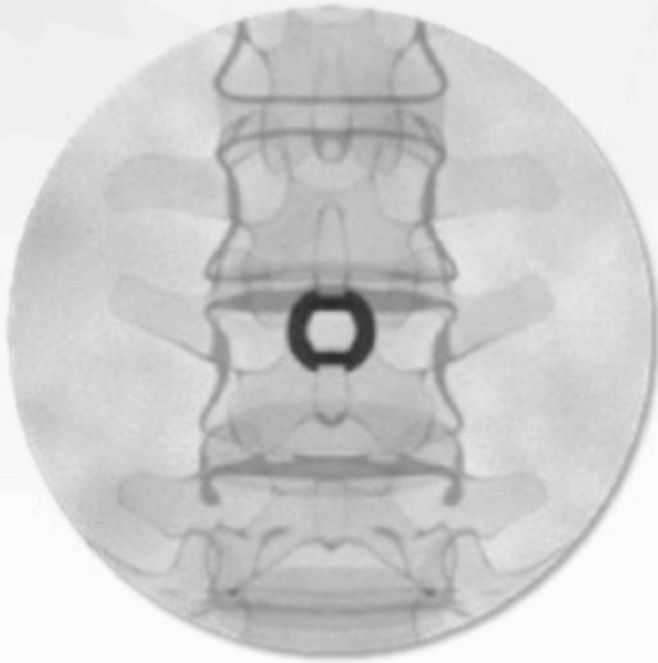
- In A/P view, insert the Cannula Assembly over the Dilator while ensuring the channels are aligned with the superior and inferior spinous processes.



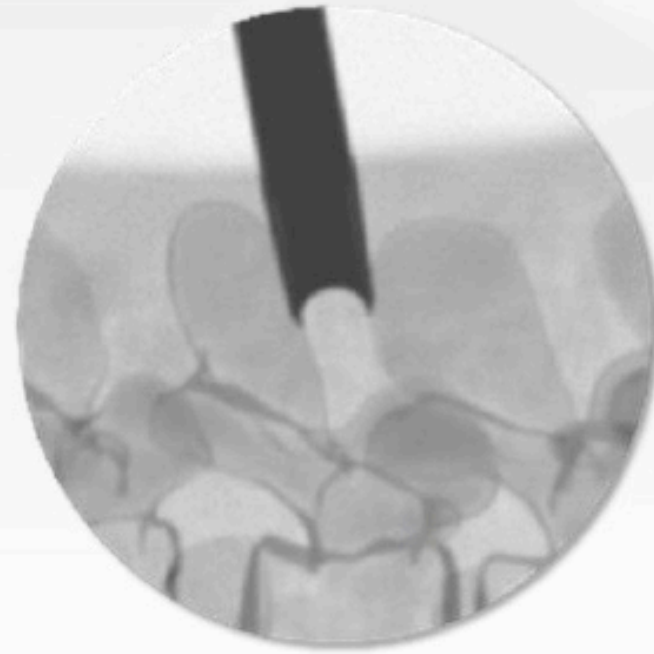
VF-LD-0184-A

©2018 Vertiflex, Inc. All rights reserved

Insertion of Cannula Assembly



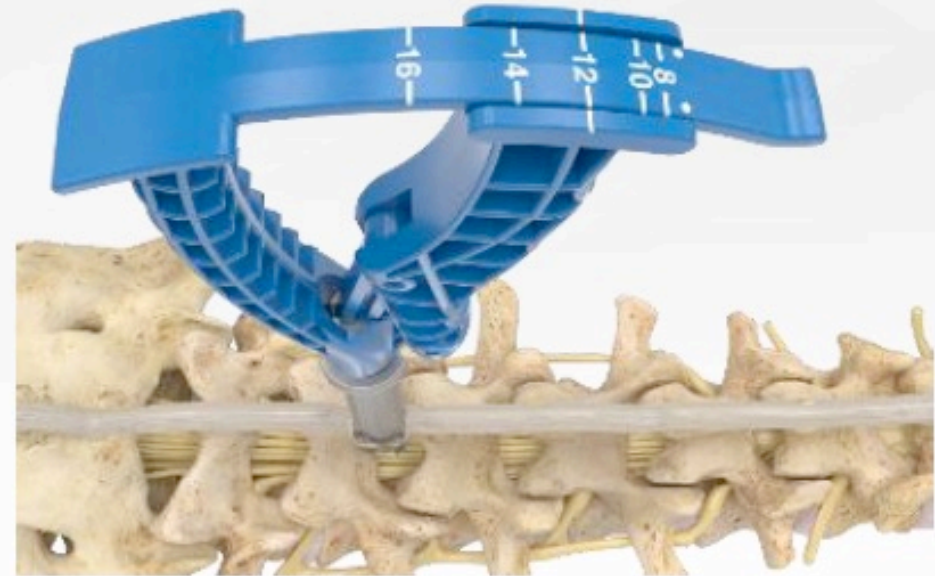
A/P View:
Cannula Position



Lateral View:
Cannula Position

Reading the Interspinous Gauge

- The measurement of the interspinous space is indicated on the instrument tab.
- When the gauge indicates a “between” size using the smaller size is recommended.



Reading the Interspinous Gauge

- The measurement corresponds with the 5 implant sizes (8, 10, 12, 14, and 16mm).

ITEM DESCRIPTION	
8mm	Gold
10mm	Blue
12mm	Magenta
14mm	Bronze
16mm	Green

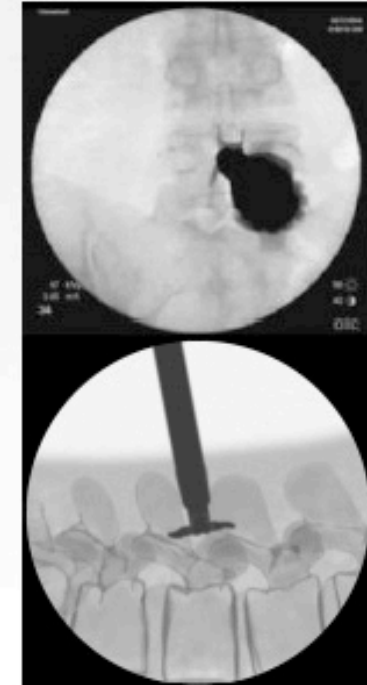
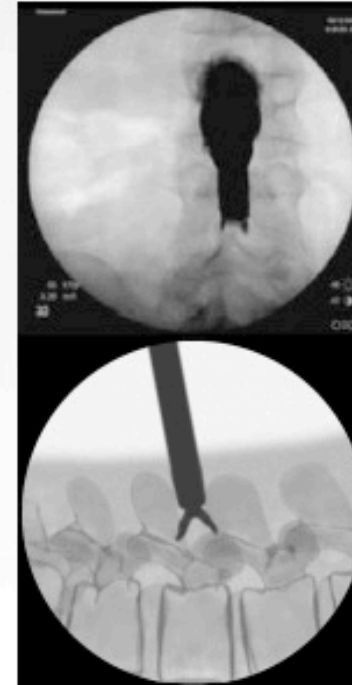
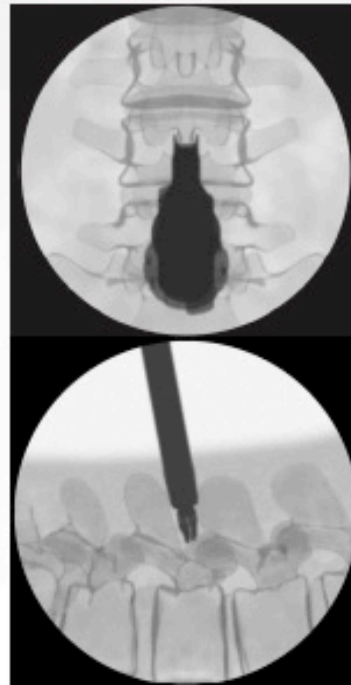


Delivering the Implant

- Under AP fluoroscopy determine the cam lobes are capturing the superior and inferior spinous processes on AP fluoroscopy.

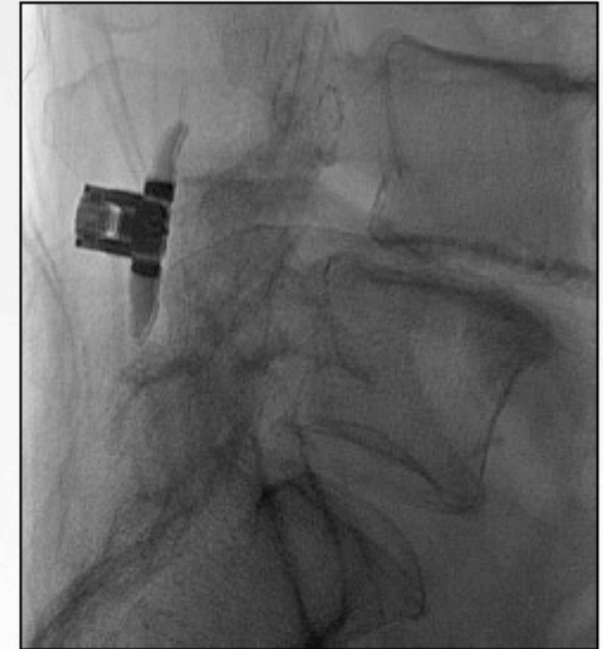
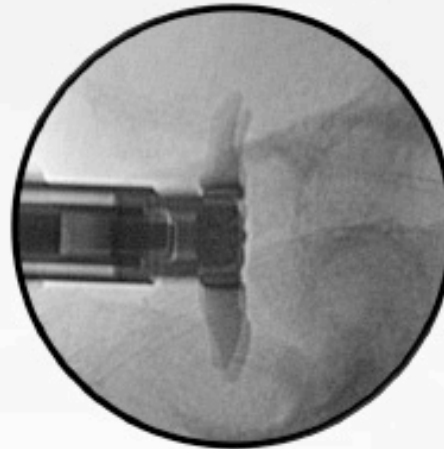A/P images
at mid
deployment

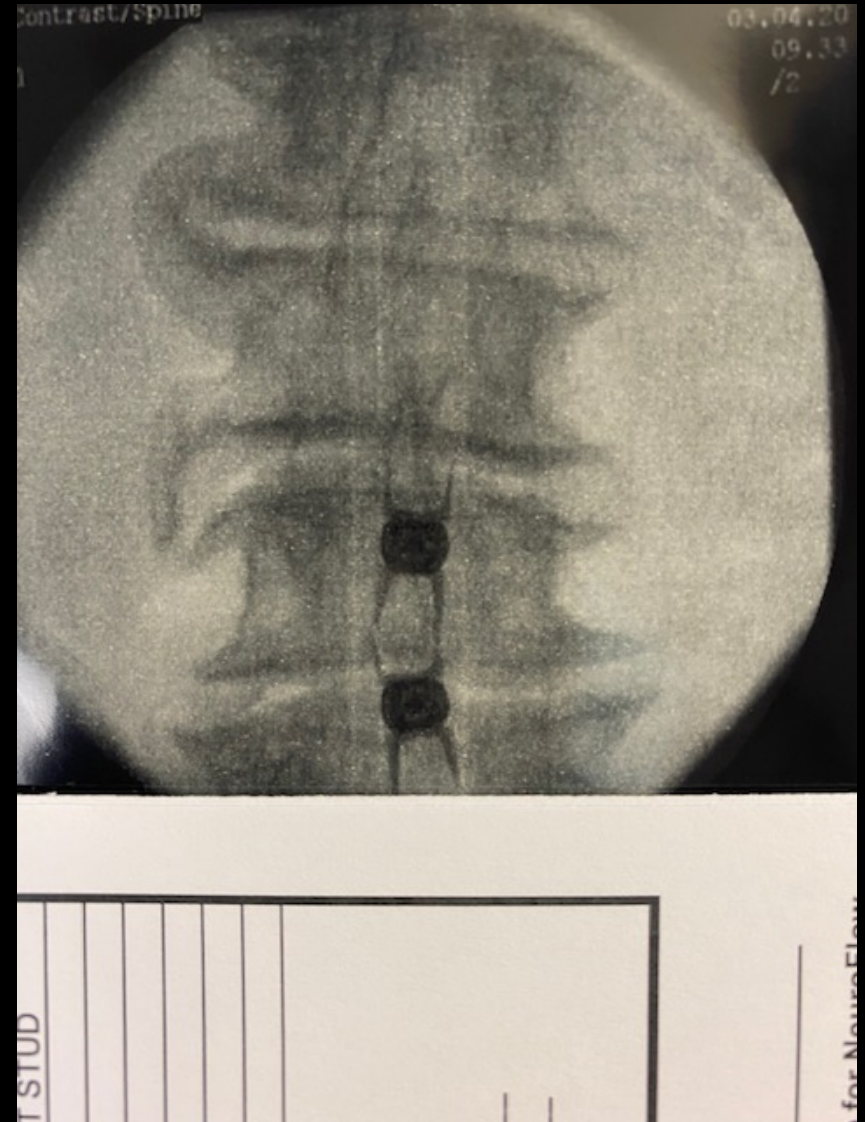
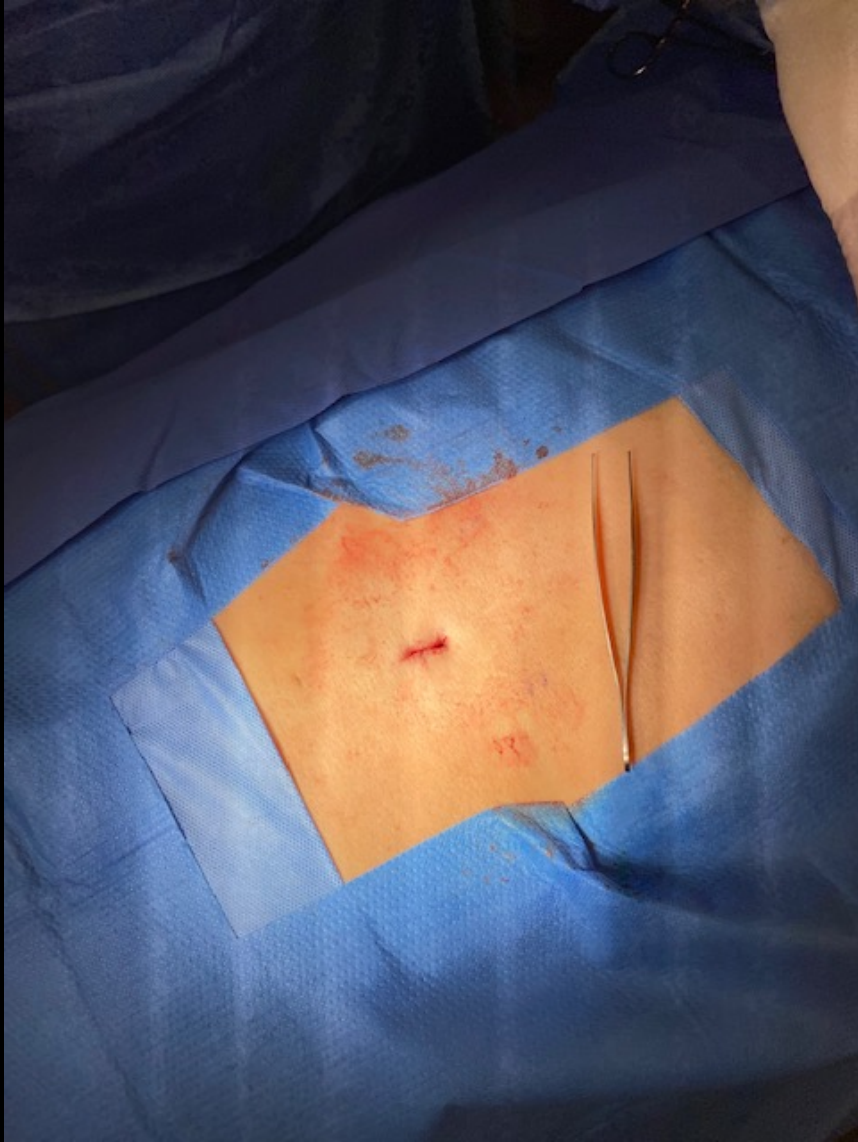Lateral images
through
deployment



Proper Ventral Placement

- It is crucial that the superior cam lobes rest ventrally, against the superior segment's lamina.
- After implant deployment, the Implant may be driven ventrally by gently tapping on the Inserters.





Questions